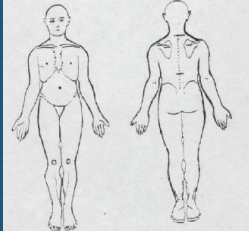



## HIP\_CASE 2\_OA



Orthopaedic Manual Physical Therapy Series  
Charlottesville 2017-2018

Eric Magrum DPT, OCS, FAAOMPT



Orthopaedic Manual Physical Therapy Series 2017-2018

**\*\* Subjective Asterisks Signs/Symptoms \*\***

(Aggravating/Easing Factors, Description/Location of symptoms, Behavior, Mechanism of injury)

- 62 yo female
- AM stiffness
- Hip pain diffuse, variable ant>lateral>post
- Gradual onset
  - Tennis season – increased play 2 -> 3x/week
- No mechanical sxs
- Improves with activity < 30', worse after

Primary HYPOTHESIS after Subjective Examination:

**Hip OA/DJD**

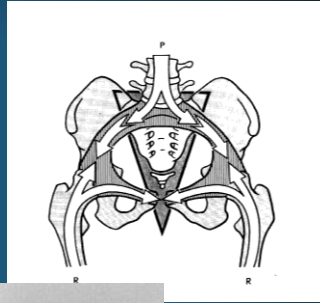


Orthopaedic Manual Physical Therapy Series 2017-2018

www.vompti.com

## Function of the Hip

- Support the weight of the trunk
- **Transmission of forces** between the pelvis and lower extremities
- **Hip DJD/OA** → Transfer forces to the lumbar spine and contralateral leg

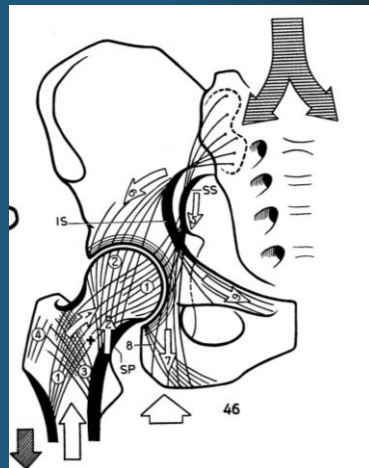


Orthopaedic Manual Physical Therapy Series 2017-2018

www.vompti.com

## Hip Forces

- Trabeculae
  - Horizontal
  - Vertical



Orthopaedic Manual Physical Therapy Series 2017-2018

www.vompti.com

Swiss engineer Karl Cullman generated **mathematical models of the femur**

In the late 1860s he noted that the **trabeculae fibers** closely resembled the **struts and braces** used in buildings

Architect Eiffel then took these ideas and designed his famous **Eiffel Tower**, the tallest structure in the world at that time, to be built with a **minimum amount of iron for maximum strength**

The **outward flares at the base** of the tower and the **internal wrought-iron braces** used in the tower closely follow the **design of trabeculae within the femur**



Orthopaedic Manual Physical Therapy Series 2017-2018

[www.vompti.com](http://www.vompti.com)

**Differential List:** (List in ranking order to screen/clear - Rule out)

- **Fem Neck Stress Fracture**
- **GTPS**
- **FAI**
- **Labral pathology**



Orthopaedic Manual Physical Therapy Series 2017-2018

[www.vompti.com](http://www.vompti.com)

## Femoral Neck Stress Fracture

### Insufficiency

#### Normal stress on abnormal bone

- Osteoporotic women
- Post menopausal → Elderly
- Poorly localized in the hip and may be referred to the thigh or back
- Prolonged corticosteroid use, radiation, methotrexate, metabolic disorders
- (-) X ray
- May need surgical stabilization

### Fatigue

#### Abnormal stress on normal bone

- Stress Reaction → Fracture
- Overuse
  - Runners, Military
- Female > Males
- Occur 2 weeks after initiation in activity
- FAT
- Stress fractures Compression side(inferior) > Tension side (superior) – high risk



## CASE REPORT

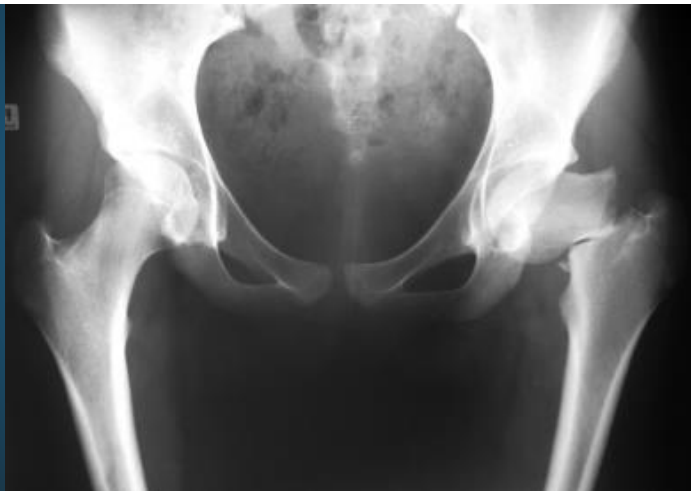A 15-year-old female cross-country runner presented with a history of 4 weeks of progressively worsening left anterior hip and groin pain. Initially, her pain occurred only upon initiation of running. Over the next 3 weeks, the patient's pain intensified and was persistent throughout the run. In the week leading up to the acute injury, the patient's pain was constant and caused her to limp. On the day of a cross-country race, she was having significant pain but was encouraged by her coach to run through the pain. Upon sprinting 20 ft (6 m) from the finish of the race, she heard a loud crack and fell to the

Goolsby MA Sports Health 2011



## A Displaced Femoral Neck Stress Fracture in an Amenorrhoeic Adolescent Female Runner

Goolsby MA Sports Health 2011

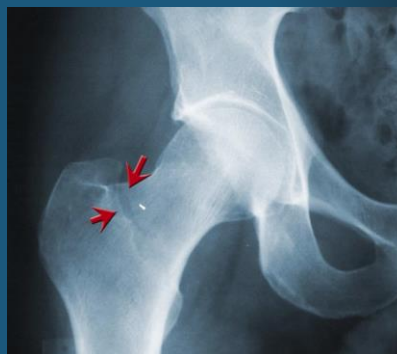

Orthopaedic Manual Physical Therapy Series 2017-2018

[www.vompti.com](http://www.vompti.com)

## Femoral Neck Stress Fracture

- Groin, medial knee pain with ROM – all planes (IR)
- Pain with WB
- Positive Hop Test – 70% accurate
- Fulcrum Test
- PPPT



Orthopaedic Manual Physical Therapy Series 2017-2018

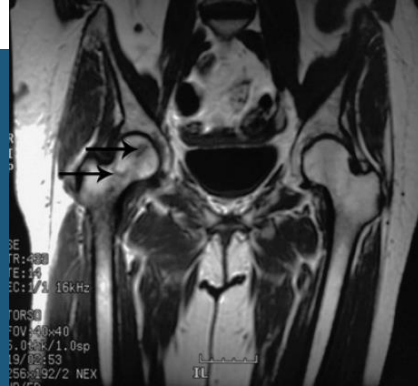
[www.vompti.com](http://www.vompti.com)

# Differential Diagnosis of a Femoral Neck/Head Stress Fracture

J Orthop Sports Phys Ther • Volume 36 • Number 2 • February 2006

Burke Gurney, PT, PhD<sup>1</sup>  
William G. Boissonnault, PT, DHSc, FAAOMPT<sup>2</sup>  
Ron Andrews, PT, PhD<sup>3</sup>

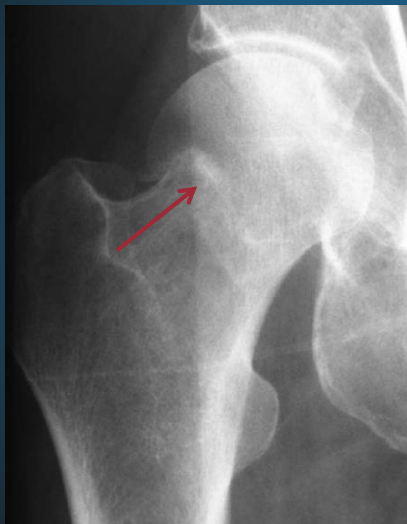- 70 yo female
- X- ray (-)
- Antalgic
- Empty end feel (ER/ABD/Flexion)
- Severely tender ant hip
- (+) MRI - Fem Head/Neck Stress fracture
- Insufficiency



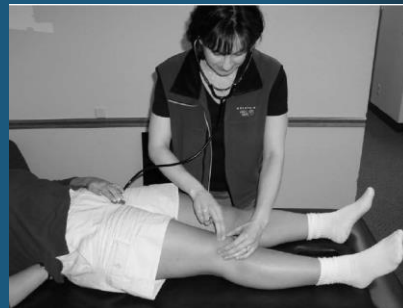Orthopaedic Manual Physical Therapy Series 2017-2018

[www.vompti.com](http://www.vompti.com)

# Use of the Patellar-Pubic Percussion Test in the Diagnosis and Management of a Patient with a Non-Displaced Hip Fracture



Leah J. Borgerding, DPT  
Pamela J. Kikillus, PT, DHSc, COMPT, OCS, FAAOMPT  
William G. Boissonnault, PT, DHSc, FAAOMPT



The Journal of Manual & Manipulative Therapy  
Vol. 15 No. 4 (2007), E78-E84



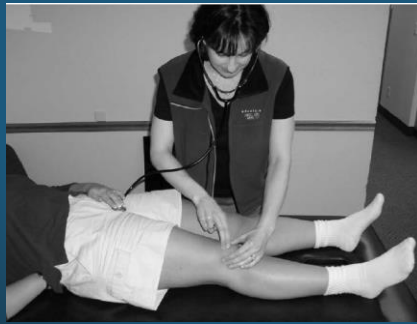Orthopaedic Manual Physical Therapy Series 2017-2018

[www.vompti.com](http://www.vompti.com)

## Diagnostic accuracy of clinical tests of the hip: a systematic review with meta-analysis Br J Sports Med (2012)

Michael P Reiman,<sup>1</sup> Adam P Goode,<sup>1</sup> Eric J Hegedus,<sup>2</sup> Chad E Cook,<sup>3</sup> Alexis A Wright<sup>2</sup>

Diagnostic test	Number studies sample size (n)	SN (95% CI)	SP (95% CI)	-LR (95% CI)	+LR (95% CI)
<b>Femoral Fracture</b>					
Patellar-Pubic Percussion	3 (n=782) <sup>50-52</sup>	95 (92 to 97)	86 (78 to 92)	0.07 (0.03 to 0.13)	6.11 (3.73 to 10.03)



(-)



Orthopaedic Manual Physical Therapy Series 2017-2018

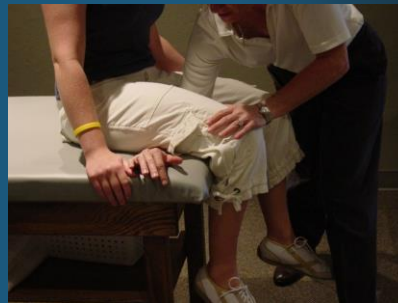www.vompti.com

- Testing for femoral shaft stress fractures

## Fulcrum Test

- (+) Reproduce pain at Femoral shaft

SN/SP (95% CI)	LR+/LR-
93 (NR)/75 (NR)	3.7/0.09
88 (NR)/13 (NR)	1.0/0.92



(-)



Orthopaedic Manual Physical Therapy Series 2017-2018

www.vompti.com

## TROCHANTERIC BURSITIS

- Pain localizing to the region of the greater trochanter, referral to lateral aspect of the thigh or into the buttock.
- Repetitive friction between the greater trochanter and the ITB with hip flexion and extension
- **91.6%** of patients diagnosed with symptomatic Trochanteric bursitis had **other** associated **pathology** affecting adjacent areas
  - **Glut medius tendonopathy, partial gluteal tears, DJD/OA hip , Lumbar referral**

Orthopaedic Manual Physical Therapy Series 2017-2018

[www.vompti.com](http://www.vompti.com)

Prospective Evaluation of Magnetic Resonance Imaging and Physical Examination Findings in Patients With Greater Trochanteric Pain Syndrome

- Women (median age 58 years)
- Median duration of symptoms was 12 months
- **MRI findings :**
- **45.8% Gluteus Medius Tear**
- **62.5% Gluteus Medius Tendinopathy** (+ tear in 6 patients)
- **8% Trochanteric bursitis**
- 4% AVN
- (+) Trendelenberg most accurate predicting a tendon tear
  - Sensitivity - 72.7%
  - Specificity - 76.9%

ARTHRITIS & RHEUMATISM  
Vol. 44, No. 9, September 2001, pp 2138-2145

Orthopaedic Manual Physical Therapy Series 2017-2018

[www.vompti.com](http://www.vompti.com)



## [ CLINICAL COMMENTARY ]

ALISON GRIMALDI, PhD<sup>1,2</sup> • ANGELA FEARON, PhD<sup>3,5</sup>

# Gluteal Tendinopathy: Integrating Pathomechanics and Clinical Features in Its Management

NOVEMBER 2015 | VOLUME 45 | NUMBER 11 | JOURNAL OF ORTHOPAEDIC & SPORTS PHYSICAL THERAPY



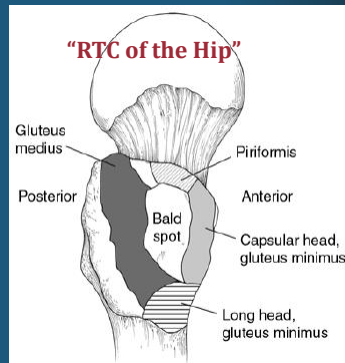
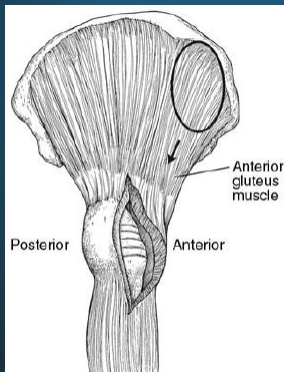
Orthopaedic Manual Physical Therapy Series 2017-2018

[www.vompti.com](http://www.vompti.com)

## Abductor Tendon Tears of the Hip: Evaluation and Management

*J Am Acad Orthop Surg* 2011;19:

The gluteus medius and minimus muscle-tendon complex is crucial for gait and stability in the hip joint. There are three clinical presentations of abductor tendon tears. Degenerative or traumatic tears of the hip abductor tendons, so-called rotator cuff tears of the hip, are seen in older patients with intractable lateral hip pain and weakness but without arthritis of the hip joint.



Orthopaedic Manual Physical Therapy Series 2017-2018

[www.vompti.com](http://www.vompti.com)

## Outcomes of Endoscopic Gluteus Medius Repair With Minimum 2-Year Follow-up

The American Journal of Sports Medicine

Vol. 41, No. 5, 2013

### Indications for Endoscopic Gluteus Medius Repair

- Peritrochanteric pain and tenderness
- Objective abductor weakness on manual strength testing
- Failure of corticosteroid injections to provide lasting therapeutic benefit
- Failure of physical therapy >3 months
- Magnetic resonance finding of full-thickness or high-grade partial-thickness tear
- Absence of significant retraction
- Endoscopic confirmation of tear amenable to repair



Orthopaedic Manual Physical Therapy Series 2017-2018

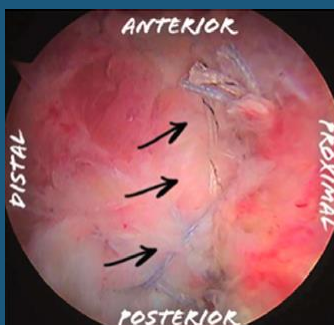
www.vompti.com

## Outcomes of Endoscopic Gluteus Medius Repair

Study of Thirty-four Patients with Minimum Two-Year Follow-up

Sivashankar Chandrasekaran, MBBS, FRACS, Chengcheng Gui, BSE, Mark R. Hutchinson, MD, Parth Lodhia, MD, Carlos Suarez-Ahedo, MD, and Benjamin G. Domb, MD

**Conclusions:** After a minimum of two years of follow-up, endoscopic surgical repair with correction of intra-articular pathological conditions was found to be an effective treatment for patients with a gluteus medius tear.




J Bone Joint Surg Am. 2015;97:1340-7



Orthopaedic Manual Physical Therapy Series 2017-2018

www.vompti.com



**(+) Weakness**  
**(-) Pain**

Test, authors	Subjects	Age (mean, SD)	Gender	Pathology	SN/SP (95% CI)	LR+ / LR-
<b>Resisted Hip Abduction</b>						
Youdas <i>et al</i> <sup>37</sup>	40 subjects	50.4, 7.2 years (controls); and 53.4, 9.0 years; (pathology)	10 F in each group	Radiographic evidence for OA	35 (NR)/90 (NR)	3.5/0.72
<b>Resisted Hip Abduction</b>						
Bird <i>et al</i> <sup>66</sup>	24 subjects	Range 36–75 years	24 F	GMed tear and/or tendinitis, partial tear	73 (NR)/46 (NR)	1.35/0.59
Lequesne <i>et al</i> <sup>68</sup>	17 subjects	68.1, 10.8 years	16 F	GMed/GMin tear and/or tendinitis, bursitis	71 (NR)/97 (NR)	23.7/0.30

**Weakness**


**Provocation**

Orthopaedic Manual Physical Therapy Series 2017-2018 [www.vompti.com](http://www.vompti.com)

## Utility of clinical tests to diagnose MRI-confirmed gluteal tendinopathy in patients presenting with lateral hip pain

Alison Grimaldi, Rebecca Mellor, Phillipa Nicolson, Paul Hodges, Kim Bennell and Bill Vicenzino  
*Br J Sports Med* 2016

Test	LR+ (95% CI)	LR- (95% CI)
Clinical diagnosis of GT	2.25 (0.94 to 5.37)	0.55 (0.35 to 0.86)†
PALP	1.5 (0.92 to 2.46)	0.43 (0.20 to 0.93)†
SLS	12.2 (0.8 to 191.5)*	0.62 (0.50 to 0.77)†
FADER	2.25 (0.58 to 8.75)	0.80 (0.62 to 1.06)
FADER-R	6.6 (0.97 to 44.98)	0.60 (0.45 to 0.79)†
FABER	2.10 (0.73 to 6.08)	0.73 (0.52 to 1.02)
ADD	1.5 (0.37 to 6.11)	0.92 (0.72 to 1.18)
ADD-R	5.7 (0.83 to 39.13)	0.66 (0.51 to 0.86)†



Orthopaedic Manual Physical Therapy Series 2017-2018 [www.vompti.com](http://www.vompti.com)

## Utility of clinical tests to diagnose MRI-confirmed gluteal tendinopathy in patients presenting with lateral hip pain

Alison Grimaldi, Rebecca Mellor, Phillipa Nicolson, Paul Hodges, Kim Bennell and Bill Vicenzino  
*Br J Sports Med* 2016

Test	Clinical Diagnosis*		Palpation		FADER-R#		SLS^	
	+ve	-ve	+ve	-ve	+ve	-ve	+ve	-ve
Pre-test probability	50%	50%	50%	50%	50%	50%	50%	50%
	↓	↓	↓	↓	↓	↓	↓	↓
Likelihood Ratio +/-	2.25	0.55	1.5	0.43	6.6	0.6	12.2	0.62
	↓	↓	↓	↓	↓	↓	↓	↓
Post-test probability~	69%	35%	60%	30%	87%	38%	92%	38%
	↓	↓	↓	↓	↓	↓	↓	↓
Interpretation and implications of the LR	The clinical diagnosis test is slightly better at ruling out the condition (15%) than it is at ruling it in (19%).		A negative palpation test would indicate that there is a low probability of GT on MRI (by 20%), whereas a positive palpation test does not improve the likelihood of GT being present on MRI.		A positive FADER-R improves confidence by approximately 40% that the lateral hip pain is present with MRI identified GT. A negative test is not so useful at ruling out GT being present on MRI (12% reduction).		A positive test conclusively establishes that GT will be present on MRI (~doubles probability), whereas a negative test will not be as useful in negating its presence (only lowers it by 12%).	

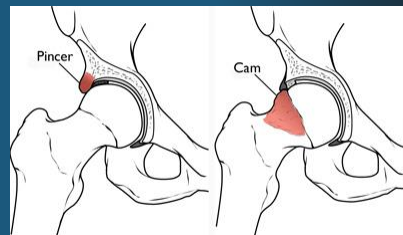


Orthopaedic Manual Physical Therapy Series 2017-2018

www.vompti.com

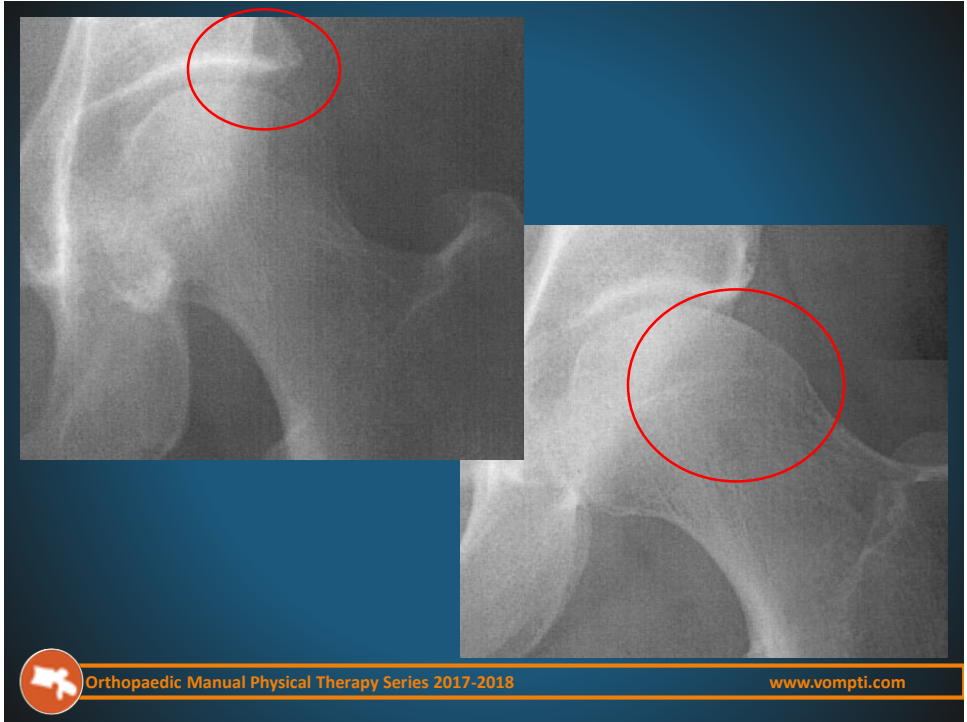
## Femoral Acetabular Impingement (FAI)

- Abnormal contact stress and joint damage around the hip
- Prolonged sitting, leaning forward, getting in and out of a vehicle, or performing a pivoting motion in sports
- Bony deformity of the femoral head or the head/neck junction, acetabulum
- FAI may initiate osteoarthritis of the hip
- Radiographs demonstrate pincer-type FAI, cam lesions, and osteophytes on the anterior femoral neck



Orthopaedic Manual Physical Therapy Series 2017-2018

www.vompti.com



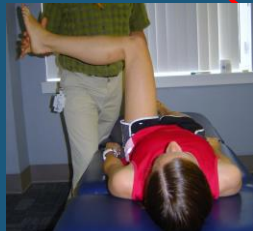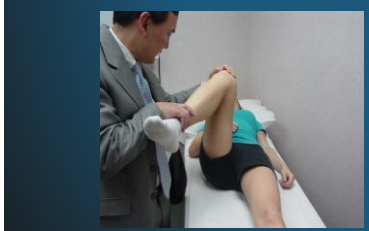
Orthopaedic Manual Physical Therapy Series 2017-2018

www.vompti.com

## Diagnostic accuracy of clinical tests of the hip: a systematic review with meta-analysis Br J Sports Med (2012)

Michael P Reiman,<sup>1</sup> Adam P Goode,<sup>1</sup> Eric J Hegedus,<sup>2</sup> Chad E Cook,<sup>3</sup> Alexis A Wright<sup>2</sup>

Diagnostic test	Number studies sample size (n)	SN (95% CI)	SP (95% CI)	-LR (95% CI)	+LR (95% CI)
<b>Labral Tear</b>					
FADDIR (MRA)	4 (n=128) <sup>40 41 43 44</sup>	94 (88 to 97)*	8 (2 to 20)*	0.48 (0.20 to 1.16)	1.02 (0.96 to 1.08)
FADDIR (Arthroscopy)	2 (n=157) <sup>42, 43</sup>	99 (95 to 100)	7 (0 to 34)	0.15 (0.01 to 2.24)	1.06 (0.92 to 1.21)
Flexion IR	3 (n=42) <sup>45-47</sup>	96 (82 to 100)	17 (12 to 54)	0.27 (0.03 to 2.34)	1.12 (0.83 to 1.51)



- (+) Pain
- (+) Limited Flex, IR
- Hard end Feel



Orthopaedic Manual Physical Therapy Series 2017-2018

www.vompti.com

## Development of a Clinical Prediction Rule for Diagnosing Hip Osteoarthritis in Individuals With Unilateral Hip Pain

- Squat - Aggravates Sx

- Active Flexion (+)

Lateral Hip pain

- (+) Scour - Lateral

Hip/Groin pain

- (-) Pain with active hip EXT

- Passive IR < 25

Number of Predictors Present	Positive Likelihood Ratio (95% CI)	Negative Likelihood Ratio (95% CI)
5	7.3 (1.1 to 49.1)	.87 (.73 to 1.1)
≥4	24.3 (4.4 to 142.1)	.53 (.35 to .80)
≥3	5.2 (2.6 to 10.9)	.33 (.17 to .66)
≥2	2.1 (1.4 to 3.1)	.31 (.13 to .78)
≥1	1.2 (.99 to 1.4)	.27 (.04 to 2.0)

*J Orthop Sports Phys Ther* 2008;38(9)



Orthopaedic Manual Physical Therapy Series 2017-2018

www.vompti.com

### THE AMERICAN COLLEGE OF RHEUMATOLOGY CRITERIA FOR THE CLASSIFICATION AND REPORTING OF OSTEOARTHRITIS OF THE HIP

**Table 4.** Clinical (history, physical examination, laboratory) classification criteria for osteoarthritis of the hip, classification tree format\*

- (+) 1. Hip pain and
- (-) 2a. Hip internal rotation <15° and
- (-) 2b. ESR ≤45 mm/hour (If ESR not available, substitute hip flexion ≤115°) or
- (+) 3a. Hip internal rotation ≥15° and
- (+) 3b. Pain on hip internal rotation and
- (+) 3c. Morning stiffness of the hip ≤60 minutes and
- (+) 3d. Age >50 years

\* This classification method yields a sensitivity of 86% and a specificity of 75%. See Figure 1 for graphic depiction of this classification tree. ESR = erythrocyte sedimentation rate (Westergren).

Arthritis and Rheumatism, Vol. 34, No. 5 (May 1991)



Orthopaedic Manual Physical Therapy Series 2017-2018

www.vompti.com

**\*\* Physical Exam “Asterisks” Signs/Symptoms \*\***  
(Special Tests, Movement/Joint Dysfunction, Posture, Palpation, etc.)

- (-) Fulcrum /PPPT
- (-) Hip ABD: Weakness > Pain
- (+) FADDIR (provocation/hard end feel)
- 4/5 Hip OA CPR
- Squat – Aggravates Sx
- Active Flexion (+) Lateral Hip pain
- (+) Scour – Lateral Hip/Groin pain
- (+) Pain IR
- AM stiffness > 60'
- Passive IR < 25
- 62 yo



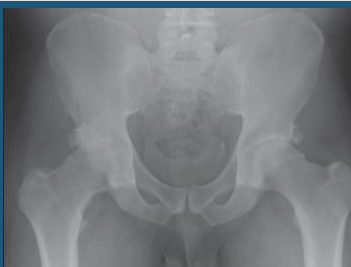Orthopaedic Manual Physical Therapy Series 2017-2018

www.vompti.com

**TABLE 1**

**KELLGREN AND LAWRENCE GRADING SCALE FOR HIP OSTEOARTHRITIS<sup>26</sup>**

Grade	Radiographic Findings
0	No evidence of joint space narrowing, osteophyte formation, or sclerosis (normal radiograph)
1	Possible narrowing of the joint space medially and possible osteophytes around the femoral head
2	Definite narrowing of the joint space, definite osteophytes, and slight sclerosis
3	Marked narrowing of the joint space, slight osteophytes, some sclerosis, and cyst formation, and deformity of the femoral head and acetabulum
4	Gross loss of joint space with sclerosis and cysts, marked deformity of femoral head and acetabulum, large osteophytes



**FIGURE 3.** Standing antero-posterior radiograph of the pelvis, with evidence of Kellgren and Lawrence grade 4 osteoarthritis in both hips.



Orthopaedic Manual Physical Therapy Series 2017-2018

www.vompti.com

MICHAEL T. CIBULKA, DPT • DOUGLAS M. WHITE, DPT • JUDITH WOEHRLE, PT, PhD • MARCIE HARRIS-HAYES, DPT  
 KEELAN ENSEKI, PT, MS • TIMOTHY L. FAGERSON, DPT • JAMES SLOVER, MD, MS • JOSEPH J. GODGES, DPT

# Hip Pain and Mobility Deficits – Hip Osteoarthritis:

*Clinical Practice Guidelines Linked to the International Classification of Functioning, Disability, and Health from the Orthopaedic Section of the American Physical Therapy Association*

J Orthop Sports Phys Ther 2009;39(4):A1-A25. doi:10.2519/jospt.2009.0301



Orthopaedic Manual Physical Therapy Series 2017-2018

www.vompti.com

### LEVELS OF EVIDENCE

Individual clinical research articles were graded according to criteria described by the Center for Evidence-Based Medicine, Oxford, United Kingdom (Table 1, below).

I	Evidence obtained from high-quality randomized controlled trials, prospective studies, or diagnostic studies
II	Evidence obtained from lesser-quality randomized controlled trials, prospective studies, or diagnostic studies (eg, improper randomization, no blinding, <80% follow-up)
III	Case-controlled studies or retrospective studies
IV	Case series
V	Expert opinion

GRADES OF RECOMMENDATION BASED ON		STRENGTH OF EVIDENCE
A	Strong evidence	A preponderance of level I and/or level II studies support the recommendation. This must include at least 1 level I study
B	Moderate evidence	A single high-quality randomized controlled trial or a preponderance of level II studies support the recommendation
C	Weak evidence	A single level II study or a preponderance of level III and IV studies, including statements of consensus by content experts support the recommendation
D	Conflicting evidence	Higher-quality studies conducted on this topic disagree with respect to their conclusions. The recommendation is based on these conflicting studies
E	Theoretical/foundational evidence	A preponderance of evidence from animal or cadaver studies, from conceptual models/principles, or from basic sciences/bench research support this conclusion
F	Expert opinion	Best practice based on the clinical experience of the guidelines development team



Orthopaedic Manual Physical Therapy Series 2017-2018

www.vompti.com



## Summary of Recommendations

### **B** PATHOANATOMICAL FEATURES

Clinicians should assess for impairments in mobility of the hip joint and strength of the surrounding muscles, especially the hip abductor muscles, when a patient presents with hip pain.

### **A** RISK FACTORS

Clinicians should consider age, hip developmental disorders, and previous hip joint injury as risk factors for hip osteoarthritis.

### **A** DIAGNOSIS/CLASSIFICATION

Moderate lateral or anterior hip pain during weight bearing, in adults over the age of 50 years, with morning stiffness less than 1 hour, with limited hip internal rotation and hip flexion by more than 15° when comparing the painful to the nonpainful side are useful clinical findings to classify a patient with hip pain into the International Statistical Classification of Diseases and Related Health Problems (ICD)



## DIFFERENTIAL DIAGNOSIS

### **V**

THE FOLLOWING DIFFERENTIAL DIAGNOSES SHOULD be considered in an individual with signs or symptoms suggestive of hip OA:

- Bursitis or tendinitis
- Chondral damage or loose bodies
- Femoral neck or pubic ramus stress fracture
- Labral tear
- Muscle strain
- Neoplasm
- Osteonecrosis of the femoral head
- Paget's disease
- Piriformis syndrome
- Psoriatic arthritis
- Rheumatoid arthritis
- Sacroiliac joint dysfunction
- Septic hip arthritis
- Referred pain as a result of an L2-3 radiculopathy



**A EXAMINATION – ACTIVITY LIMITATION AND PARTICIPATION RESTRICTION MEASURES**

Clinicians should utilize easily reproducible physical performance measures, such as the 6-minute walk, self-paced walk, stair measure, and timed up-and-go tests to assess activity limitation and participation restrictions associated with their patient's hip pain and to assess the changes in the patient's level of function over the episode of care.

**B INTERVENTIONS – PATIENT EDUCATION**

Clinicians should consider the use of patient education to teach activity modification, exercise, weight reduction when overweight, and methods of unloading the arthritic joints.

**C INTERVENTIONS – FUNCTIONAL, GAIT, AND BALANCE TRAINING**

Functional, gait, and balance training, including the use of assistive devices such as canes, crutches, and walkers, can be used in patients with hip osteoarthritis to improve function associated with weight-bearing activities.



**B INTERVENTIONS – MANUAL THERAPY**

Clinicians should consider the use of manual therapy procedures to provide short-term pain relief and improve hip mobility and function in patients with mild hip osteoarthritis.

**B INTERVENTIONS – FLEXIBILITY, STRENGTHENING, AND ENDURANCE EXERCISES**

Clinicians should consider the use of flexibility, strengthening, and endurance exercises in patients with hip osteoarthritis

## Manual Therapy + Exercise



# Comparison of Manual Therapy and Exercise Therapy in Osteoarthritis of the Hip: A Randomized Clinical Trial

Arthritis & Rheumatism (Arthritis Care & Research)  
Vol. 51, No. 5, October 15, 2004, pp 722-729

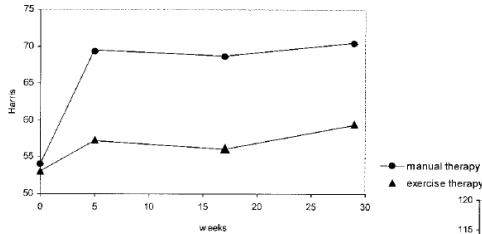


Figure 2. Results of the Harris Hip Score.

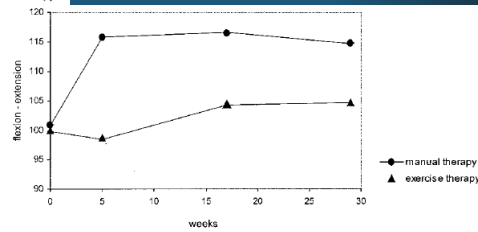


Figure 3. Results on range of joint motion from flexion to extension.



Orthopaedic Manual Physical Therapy Series 2017-2018

www.vompti.com



## Effect of Physical Therapy on Pain and Function in Patients With Hip Osteoarthritis A Randomized Clinical Trial

Kim L. Bennell, PhD; Thorene Egerton, PhD; Joel Martin, BAppSc; J. Haxby Abbott, PhD; Ben Metcalf, BSc; Fiona McManus, BPhysio; Kevin Sims, PhD; Yong-Hao Pua, PhD; Tim V. Wrigley, MSc; Andrew Forbes, PhD; Catherine Smith, MSc (Applied Statistics); Anthony Harris, MSc; Rachele Buchbinder, PhD

### Conclusions

A multimodal physical therapy program conferred no additional clinical benefit over a realistic sham for people with hip osteoarthritis and was associated with relatively frequent but mild adverse effects. These results question the benefits of such a physical therapy program for this patient population.

JAMA May 21, 2014 Volume 311, Number 19

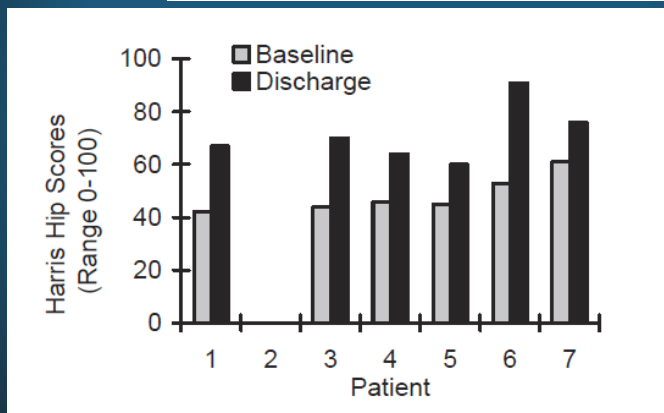


Orthopaedic Manual Physical Therapy Series 2017-2018

www.vompti.com

# Clinical Outcomes Following Manual Physical Therapy and Exercise for Hip Osteoarthritis: A Case Series

J Orthop Sports Phys Ther • Volume 36 • Number 8 • August 2006



Orthopaedic Manual Physical Therapy Series 2017-2018

www.vompti.com

# Clinical Outcomes Following Manual Physical Therapy and Exercise for Hip Osteoarthritis: A Case Series

J Orthop Sports Phys Ther • Volume 36 • Number 8 • August 2006

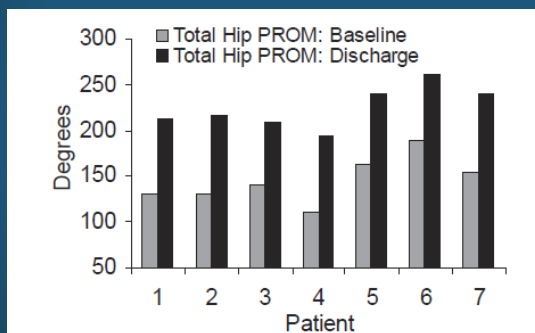


FIGURE 8. Patients total hip passive range of motion (PROM) at baseline and discharge. PROM includes flexion, extension, internal rotation, external rotation, and abduction.



Orthopaedic Manual Physical Therapy Series 2017-2018

www.vompti.com

# Clinical Outcomes Following Manual Physical Therapy and Exercise for Hip Osteoarthritis: A Case Series

J Orthop Sports Phys Ther • Volume 36 • Number 8 • August 2006

TABLE 6. Hip mobilization/manipulation techniques.

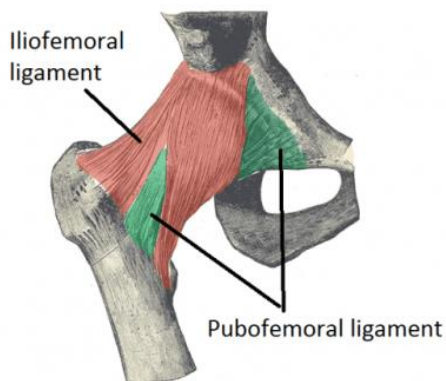
Supine
<ul style="list-style-type: none"> <li>• Long-axis nonthrust oscillations in slight abduction</li> <li>• Progression of above into abduction</li> <li>• Nonthrust lateral glides of femur with a belt</li> <li>• Lateral glides with combined rotations</li> <li>• Long-axis thrust mobilization/manipulation in a loose-packed position</li> <li>• Thrust mobilization/manipulation in less abduction (&gt;15°)</li> <li>• Hip flexion nonthrust inferior glides</li> </ul>
Sidelying
<ul style="list-style-type: none"> <li>• Anterior femoral nonthrust mobilization/manipulation</li> <li>• Hip distraction with nonthrust medial femoral glide</li> <li>• Hip distraction nonthrust medial glide plus abduction</li> </ul>
Prone
<ul style="list-style-type: none"> <li>• Anterior nonthrust femoral glides</li> <li>• Anterior nonthrust glides in figure-four position</li> </ul>



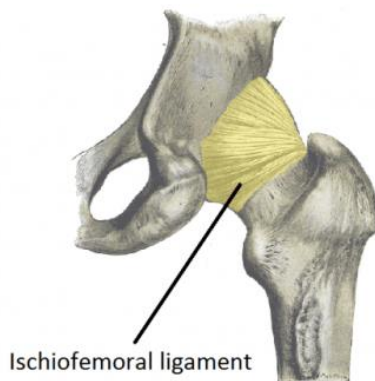
Orthopaedic Manual Physical Therapy Series 2017-2018

www.vompti.com

## Anterior



## Posterior



© teachmeanatomy



Orthopaedic Manual Physical Therapy Series 2017-2018

www.vompti.com

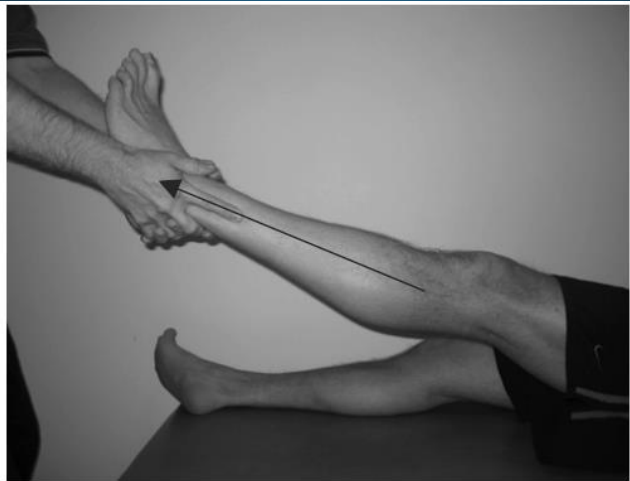
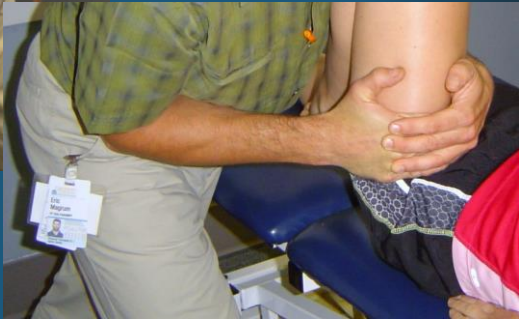
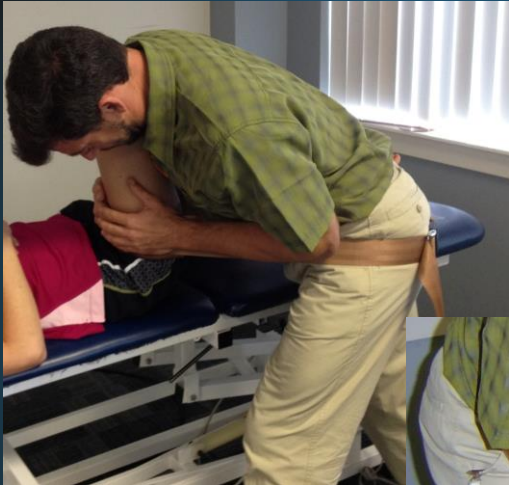FIGURE 1. Long-axis nonthrust mobilization/manipulation of the hip in 15° to 30° abduction and 15° to 30° flexion.



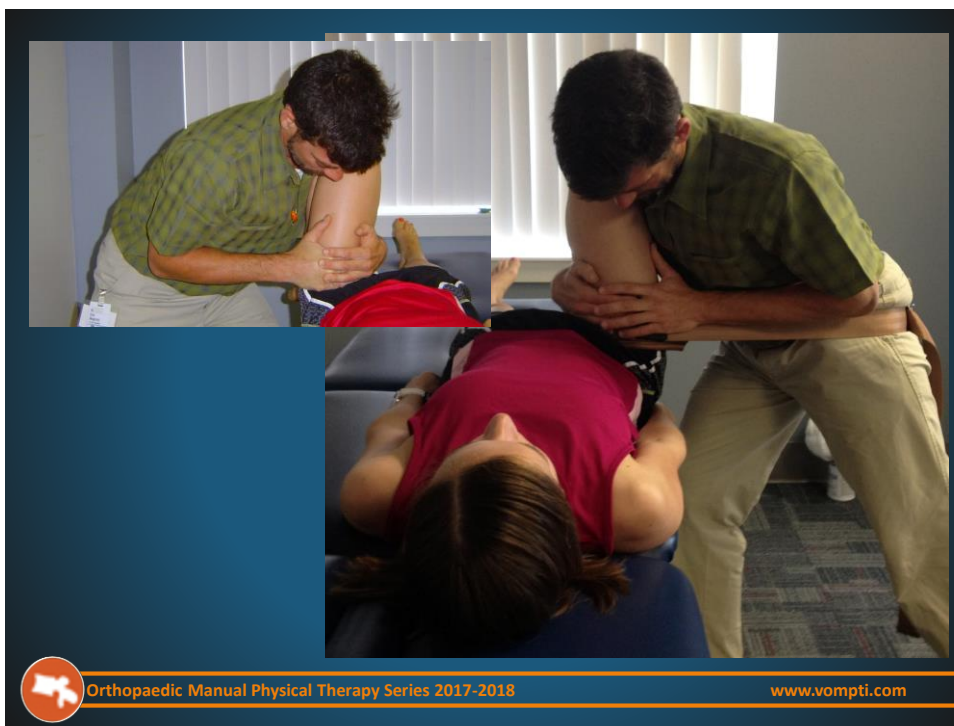
Orthopaedic Manual Physical Therapy Series 2017-2018

[www.vompti.com](http://www.vompti.com)



Orthopaedic Manual Physical Therapy Series 2017-2018

[www.vompti.com](http://www.vompti.com)



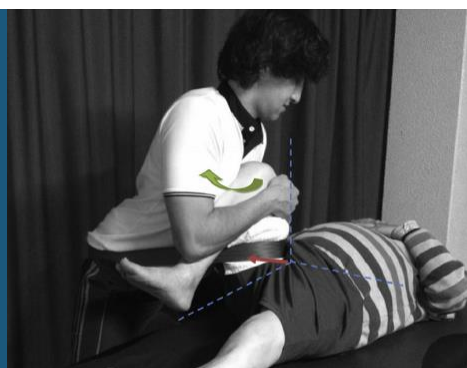
Orthopaedic Manual Physical Therapy Series 2017-2018

www.vompti.com

Immediate effects of hip mobilization with movement in patients with hip osteoarthritis: A randomised controlled trial<sup>☆</sup> *Manual Therapy xxx (2015) 1–6*

Carlos Beselga<sup>a,b</sup>, Francisco Neto<sup>c</sup>, Francisco Albuquerque-Sendín<sup>d,e,\*</sup>, Toby Hall<sup>f</sup>, Natália Oliveira-Campelo<sup>g</sup>

- **MWM: Lateral distraction with IR**
- **NPS: Decreased 2 points**
- **Flexion increased 12 degrees**
- **IR increased 4.4 degrees**
- **Functional Improvements:**
  - **Timed Get up and Go**
  - **30s Chair Stand test**
  - **40m Walk test**



Legend: - - - - Axes ← Lateral glide  
 ↻ Passive movement medial hip rotation

Fig. 2. Internal rotation mobilization-with-movement technique.



Orthopaedic Manual Physical Therapy Series 2017-2018

www.vompti.com

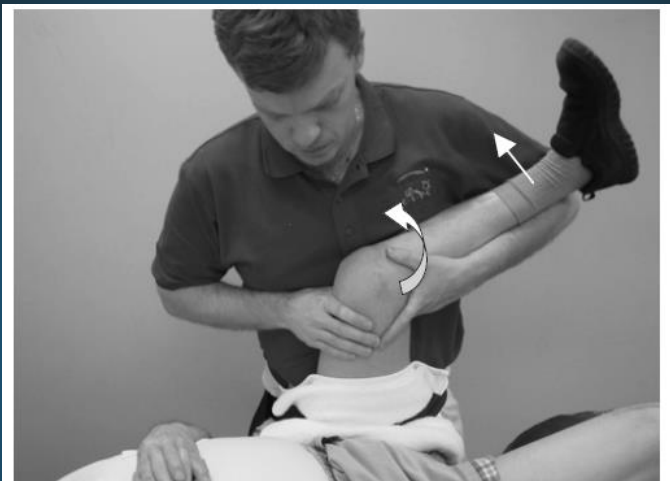
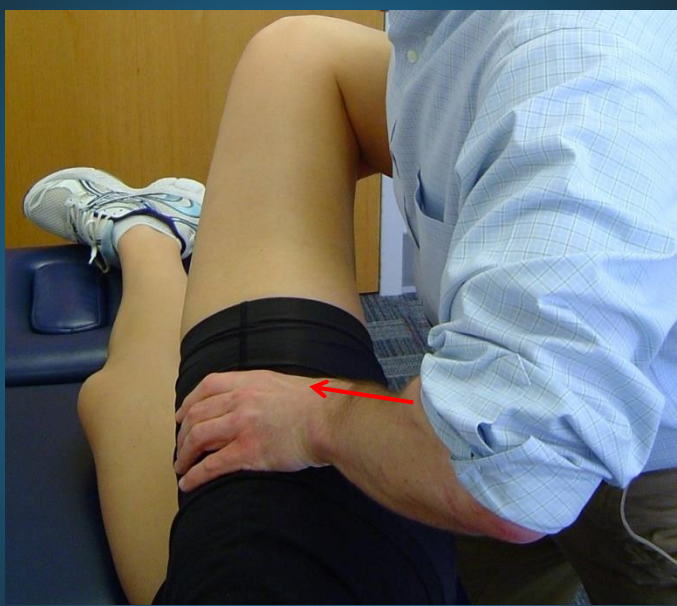
FIGURE 2. Lateral nonthrust mobilization/manipulation of the hip with a belt, combining a lateral femoral glide with internal rotation.



Orthopaedic Manual Physical Therapy Series 2017-2018

www.vompti.com

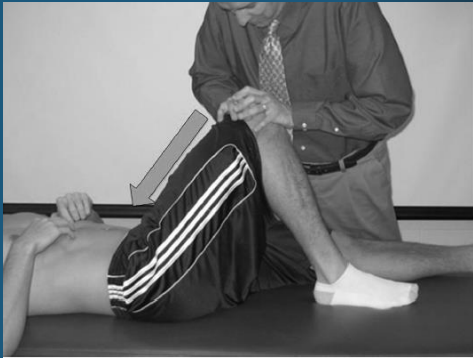
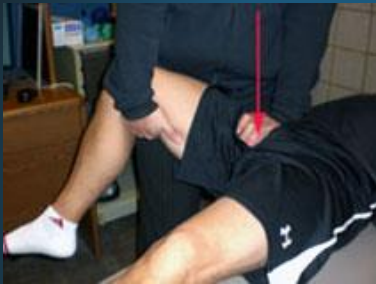

Orthopaedic Manual Physical Therapy Series 2017-2018

www.vompti.com



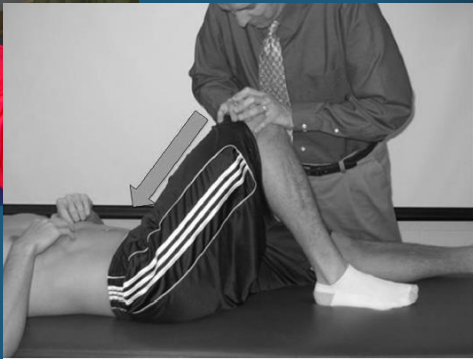
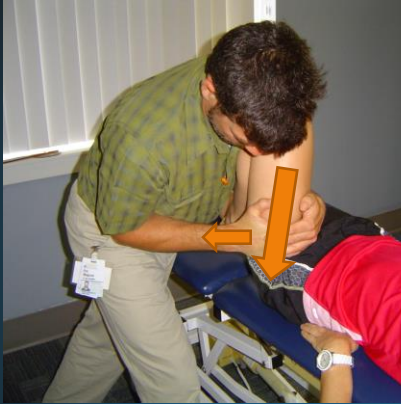# Posterior Hip Mobilization



Orthopaedic Manual Physical Therapy Series 2017-2018

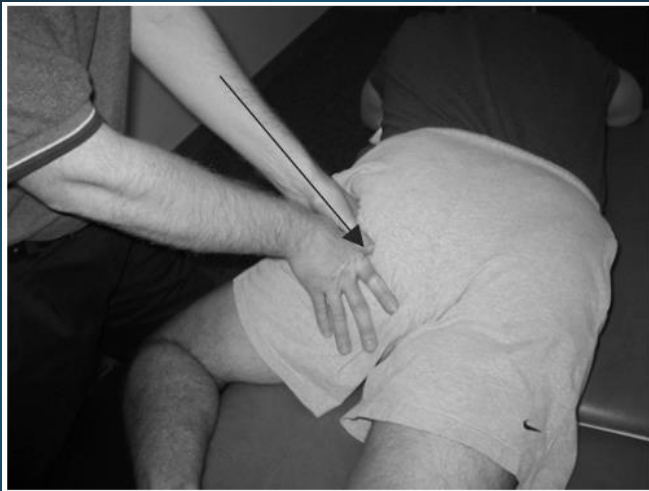[www.vompti.com](http://www.vompti.com)

# Posterior Glide at 90 Flexion

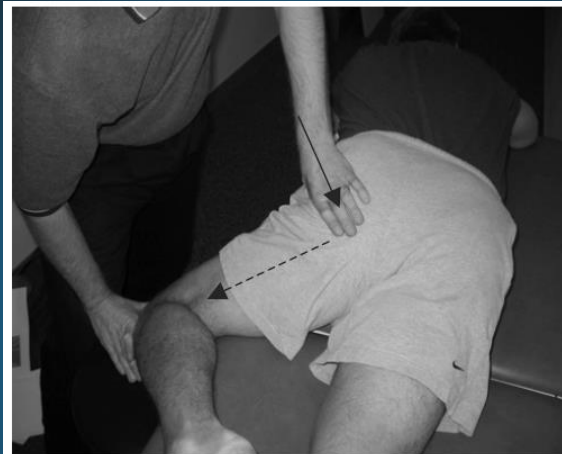

Orthopaedic Manual Physical Therapy Series 2017-2018

[www.vompti.com](http://www.vompti.com)

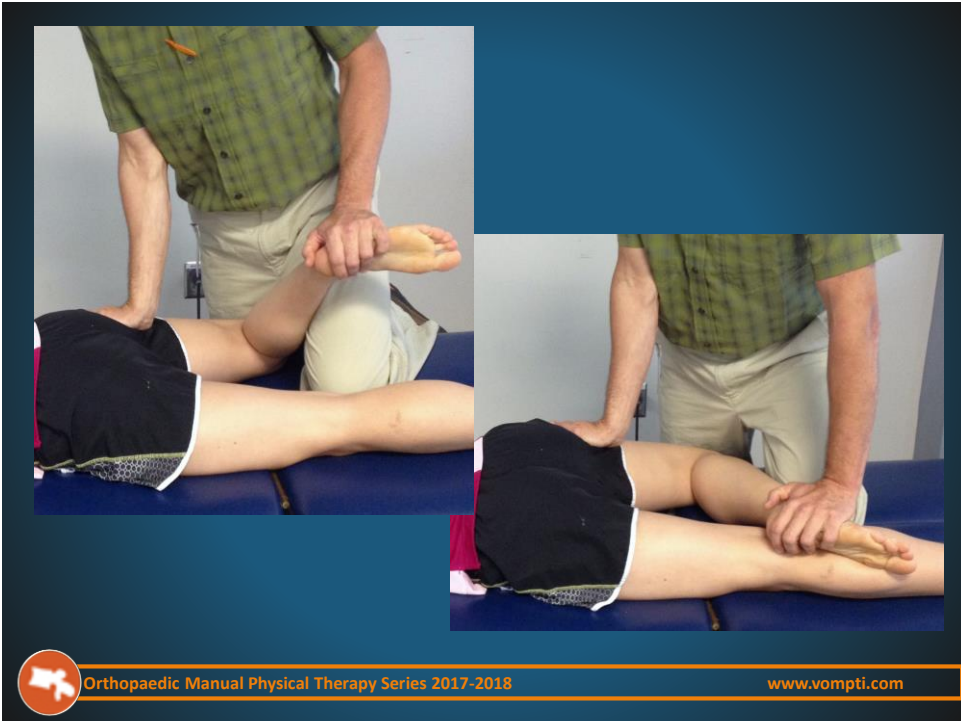
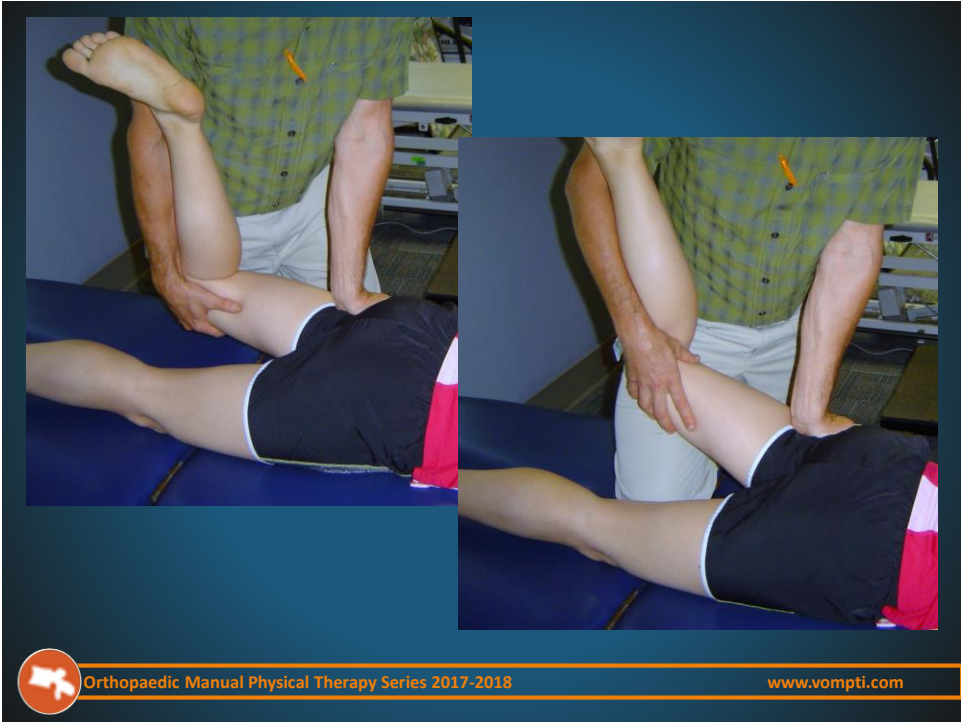
**FIGURE 4.** Anterior hip nonthrust mobilization/manipulation in modified figure-four position, allowing for less available abduction (knee on stool).



**FIGURE 5.** Anterior hip nonthrust mobilization/manipulation, using an active contraction of the hip external rotators to assist with the anterior glide. The patient actively pushes the knee into the therapist's hand, facilitating a contraction, as the therapist mobilizes the femur anteriorly with the proximal hand (dashed line represents direction of push from patient's muscle contraction).





## Exercise and Manual Physiotherapy Arthritis Research Trial (EMPART) for Osteoarthritis of the Hip: A Multicenter Randomized Controlled Trial

- No significant difference in WOMAC scores between the Exercise and Exercise +Manual Therapy groups at 9 or 18 weeks
- Except **patient satisfaction with outcomes**, which was **higher in the ET+MT group**
- Improvements in WOMAC, hip ROM, and patient-perceived change occurred in both treatment groups compared with the control group.



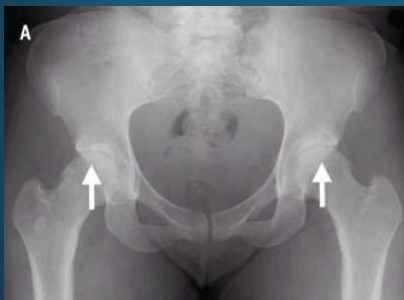Archives of Physical Medicine and Rehabilitation 2013;94:302-14



Orthopaedic Manual Physical Therapy Series 2017-2018

www.vompti.com

## Conservative Management of a Young Adult With Hip Arthrosis



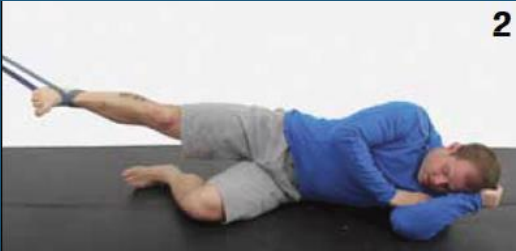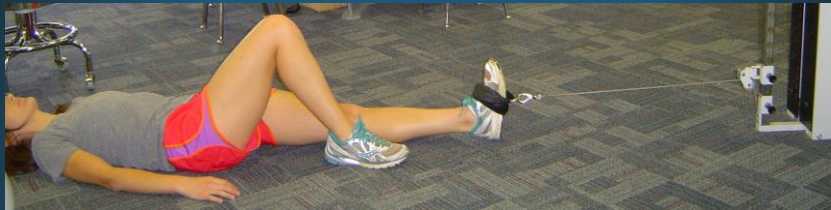J Orthop Sports Phys Ther 2009;39(12):858-866.



Orthopaedic Manual Physical Therapy Series 2017-2018

www.vompti.com

# Long Axis Distraction



Orthopaedic Manual Physical Therapy Series 2017-2018

[www.vompti.com](http://www.vompti.com)

# Posterior Glide Quadruped Flexion



Orthopaedic Manual Physical Therapy Series 2017-2018

[www.vompti.com](http://www.vompti.com)


# Dynamic Self Posterior Mobilization



Orthopaedic Manual Physical Therapy Series 2017-2018

[www.vompti.com](http://www.vompti.com)

# Posterior/Lateral Glide ½ Kneeling/Lunge



Orthopaedic Manual Physical Therapy Series 2017-2018

[www.vompti.com](http://www.vompti.com)



Orthopaedic Manual Physical Therapy Series 2017-2018


[www.vompti.com](http://www.vompti.com)

# Lateral Glide Internal/External Rotation



Orthopaedic Manual Physical Therapy Series 2017-2018

[www.vompti.com](http://www.vompti.com)



NEW YORK TIMES BESTSELLER

# Becoming a Supple Leopard

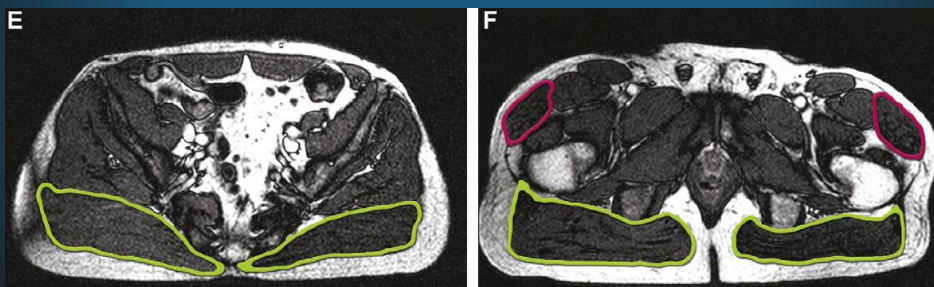
The Ultimate Guide to Resolving Pain, Preventing Injury, and Optimizing Athletic Performance

Dr. Kelly Starrett  
with Glen Cordoza

Orthopaedic Manual Physical Therapy Series 2017-2018 [www.vompti.com](http://www.vompti.com)

The association between degenerative hip joint pathology and size of the gluteus maximus and tensor fascia lata muscles

- 21% Atrophy Upper Glut Max – **Advanced OA** – (EXT ROT)
- 19.7% Atrophy Lower Glut Max (EXT)
- No difference TFL



Manual Therapy 14 (2009) 611–617

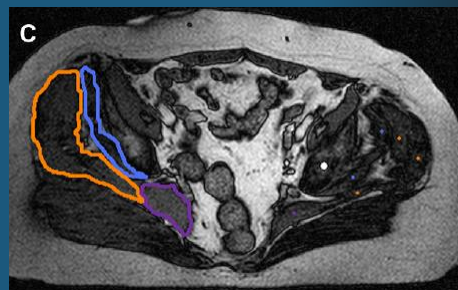
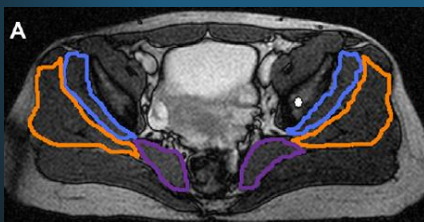
Orthopaedic Manual Physical Therapy Series 2017-2018 [www.vompti.com](http://www.vompti.com)



The association between degenerative hip joint pathology and size of the gluteus medius, gluteus minimus and piriformis muscles

Manual Therapy 14 (2009) 605-610

- Advanced OA → Glut Med (14%), Minimus (8.3%), Piriformis (12%) Atrophy
- **Mild OA → Glut Med (16%) Hypertrophy**

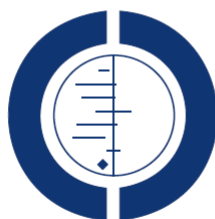


Orthopaedic Manual Physical Therapy Series 2017-2018

www.vompti.com

Exercise for osteoarthritis of the hip (Review)

Fransen M, McConnell S, Hernandez-Molina G, Reichenbach S



THE COCHRANE  
COLLABORATION®

Authors' conclusions

Pooling the results of these 10 RCTs demonstrated that land-based therapeutic exercise programmes can reduce pain and improve physical function among people with symptomatic hip OA.



Orthopaedic Manual Physical Therapy Series 2017-2018

www.vompti.com

<LEAP>  
LINKING EVIDENCE AND PRACTICE

## Exercise for Osteoarthritis of the Hip

Nolwenn Poquet, Matthew Williams, Kim L. Bennell

November 2016
Volume 96 Number 11 Physical Therapy

**Case #29: Applying Evidence to a Patient With Osteoarthritis of the Hip**  
Can exercise help this patient?

How did the results of the Cochrane systematic review apply to Mrs J?

How well do the outcomes of the intervention provided to the patient match those suggested by the systematic review?

Can you apply the results of this systematic review to your own patients?

Orthopaedic Manual Physical Therapy Series 2017-2018
www.vompti.com

## Can local muscles augment stability in the hip?

### A narrative literature review

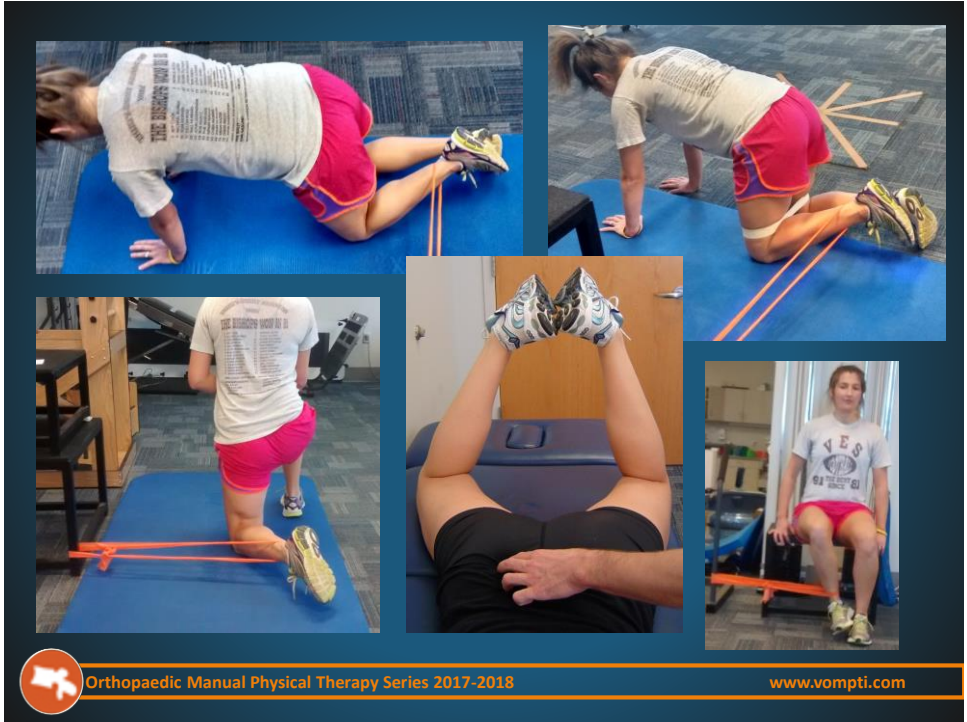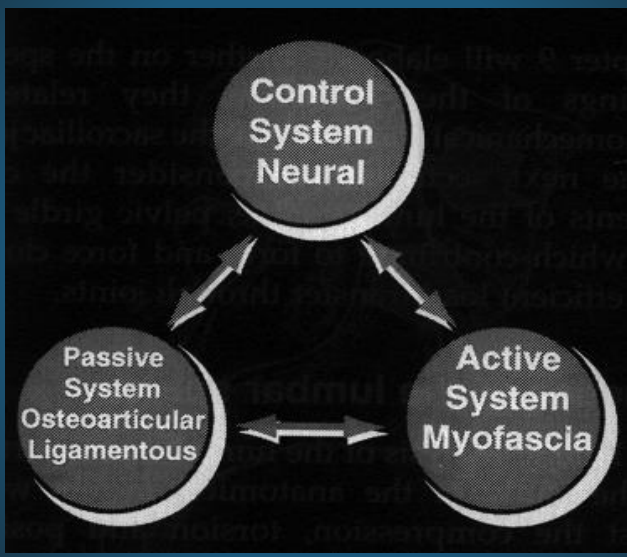
Proposed mechanisms for the development of degenerative hip disease as a result of multi-factorial instability.

```

graph LR
    A[Generalised ligamentous laxity] --> B[Capsuloligamentous laxity of hip]
    C[Repetitive low load in normal hip] --> B
    D[Acute high load in normal hip] --> B
    E[Developmental dysplasia of the hip] --> F[IF active stabilisers cannot augment loss of passive stability]
    B --> F
    F --> G[Increased femoral head translation]
    G --> H[Chondropathy]
    H --> I[Degenerative hip disease]
    F --> J[Labral injury]
    J --> G
    J --> K[Reduced labral seal]
    L[Femoroacetabular impingement] --> J
    M[Abnormal morphology of acetabulum, femoral head or neck] --> L
    
```

Orthopaedic Manual Physical Therapy Series 2017-2018
J Musculoskelet Neuronal Interact 2013; 13(1):1-12
www.vompti.com

# Panjabi's Components of Stability



# A literature review of studies evaluating gluteus maximus and gluteus medius activation during rehabilitation exercises

Physiotherapy Theory and Practice, 28(4):257-268, 2012



Orthopaedic Manual Physical Therapy Series 2017-2018

www.vompti.com

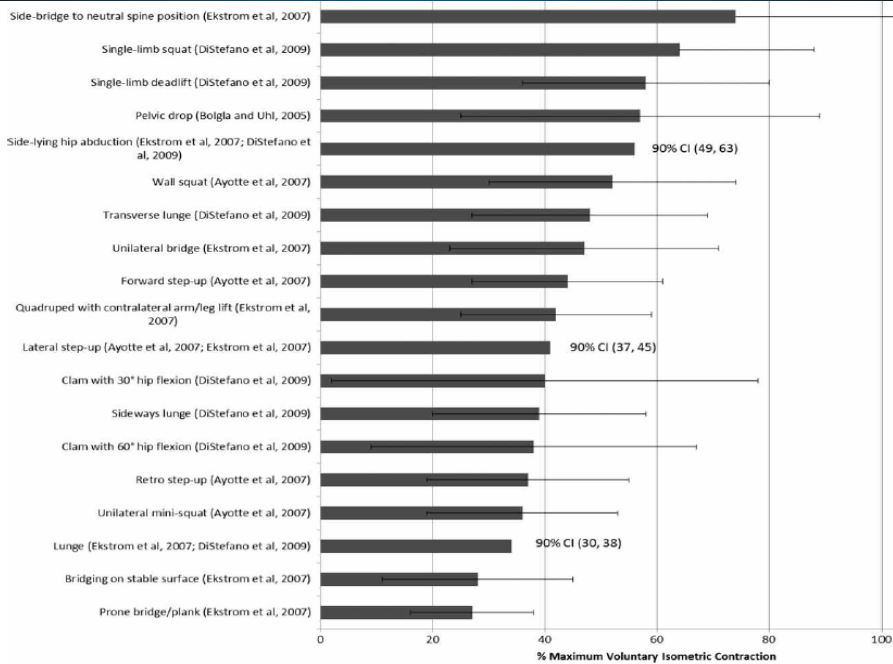
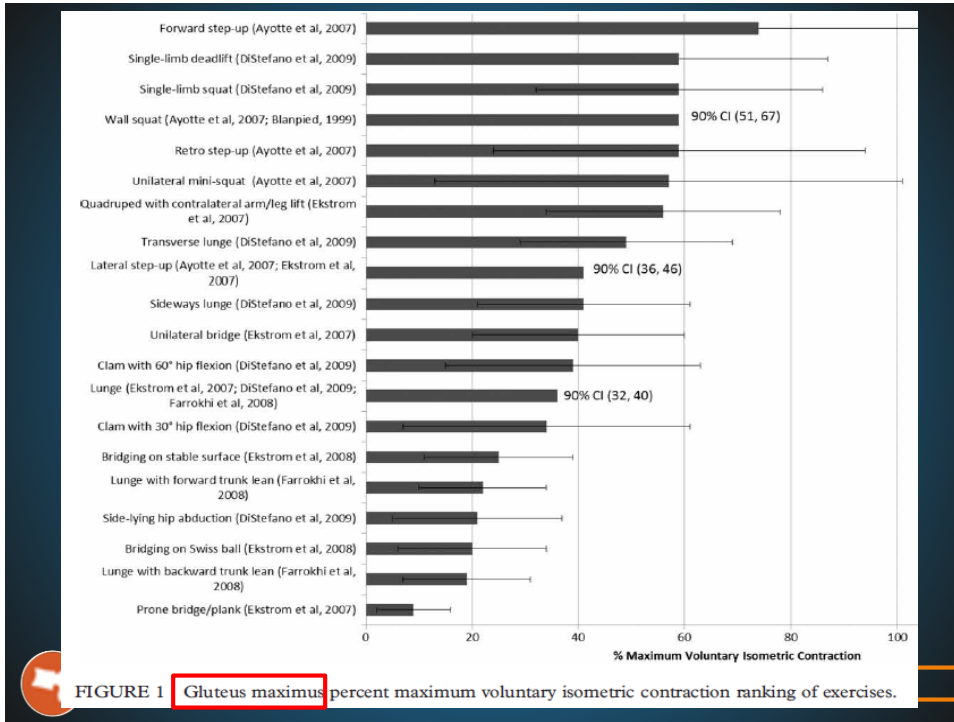



FIGURE 2 **Gluteus medius** percent maximum voluntary isometric contraction ranking of exercises.



RESEARCH REPORT

## Gluteal Muscle Activation During Common Therapeutic Exercises


*J Orthop Sports Phys Ther 2009;39(7):532-540. doi:10.2519/jospt.2009.2796*  
 Lindsay J. DiStefano, J. Troy Blackburn, Stephen W. Marshall, Darin A. Padua



VOLUME 39 | NUMBER 7 | JULY 2009

© 2009 JOURNAL OF ORTHOPAEDIC & SPORTS PHYSICAL THERAPY

---

 Orthopaedic Manual Physical Therapy Series 2017-2018
[www.vompti.com](http://www.vompti.com)

GLUTEAL MUSCLE ACTIVATION DURING COMMON THERAPEUTIC EXERCISES

TABLE 2	NORMALIZED GLUTEUS MEDIUS MEAN SIGNAL AMPLITUDE (% MVIC)	
	Exercise	Mean ± SD (95% CI)
Side-lying hip abduction	81 ± 42 (62, 101)	
Single-limb squat	64 ± 24 (53, 75)	
Lateral band walk	61 ± 34 (46, 76)	
Single-limb deadlift	58 ± 25 (47, 70)	
Sideways hop	57 ± 35 (41, 73)	
Transverse hop*	48 ± 25 (37, 59)	
Transverse lunge*	48 ± 21 (38, 57)	
Forward hop*	45 ± 21 (38, 57)	
Forward lunge* <sup>†</sup>	42 ± 21 (33, 52)	
Clam with 30° hip flexion*	40 ± 38 (23, 57)	
Sideways lunge* <sup>†</sup>	39 ± 19 (30, 47)	
Clam with 60° hip flexion* <sup>†</sup>	38 ± 29 (25, 51)	

*Abbreviations: CI, confidence interval; MVIC, maximum voluntary isometric contraction.  
\* Exercises are significantly different than the hip abduction exercise (P<.05).  
<sup>†</sup> Exercises are significantly different from the single-limb squat (P<.05).*

Research Report:  
*Gluteal Muscle Activation During Common Therapeutic Exercises*  
| VOLUME 39 | NUMBER 7 | JULY 2009 | © 2009 JOURNAL OF ORTHOPAEDIC & SPORTS PHYSICAL THERAPY

**JOSPT**  
Journal of Orthopaedic & Sports Physical Therapy



GLUTEAL MUSCLE ACTIVATION DURING COMMON THERAPEUTIC EXERCISES

TABLE 3	NORMALIZED GLUTEUS MAXIMUS MEAN SIGNAL AMPLITUDE (% MVIC)	
	Exercise	Mean ± SD (95% CI)
Single-limb squat	59 ± 27 (47, 72)	
Single-limb deadlift	59 ± 28 (46, 71)	
Transverse lunge	49 ± 20 (39, 58)	
Forward lunge	44 ± 23 (33, 54)	
Sideways lunge	41 ± 20 (32, 50)	
Side-lying hip abduction	39 ± 18 (31, 47)	
Sideways hop	30 ± 19 (31, 48)	
Clam with 60° hip flexion	39 ± 34 (24, 54)	
Transverse hop* <sup>†</sup>	35 ± 16 (28, 43)	
Forward hop* <sup>†</sup>	35 ± 22 (25, 45)	
Clam with 30° hip flexion* <sup>†</sup>	34 ± 27 (21, 46)	
Lateral band walk* <sup>‡</sup>	27 ± 16 (20, 35)	

*Abbreviations: CI, confidence interval; MVIC, maximum voluntary isometric contraction.  
\* Exercises are significantly different than the single-limb squat (P<.05).  
<sup>†</sup> Exercises are significantly different from the single-limb deadlift (P<.05).  
<sup>‡</sup> Exercises are significantly different from the transverse lunge (P<.05).*

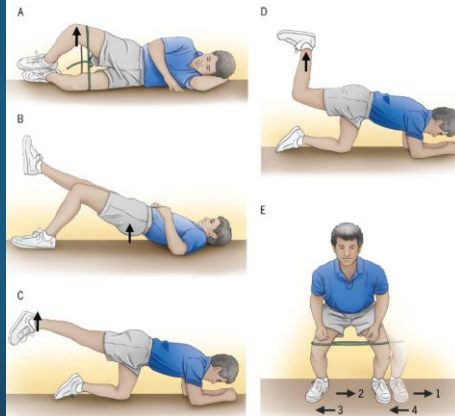
Research Report:  
*Gluteal Muscle Activation During Common Therapeutic Exercises*  
| VOLUME 39 | NUMBER 7 | JULY 2009 | © 2009 JOURNAL OF ORTHOPAEDIC & SPORTS PHYSICAL THERAPY

**JOSPT**  
Journal of Orthopaedic & Sports Physical Therapy



# Which Exercises Target the Gluteal Muscles While Minimizing Activation of the Tensor Fascia Lata? Electromyographic Assessment Using Fine-Wire Electrodes

FEBRUARY 2013 | VOLUME 43 | NUMBER 2 | JOURNAL OF ORTHOPAEDIC & SPORTS PHYSICAL THERAPY



Orthopaedic Manual Physical Therapy Series 2017-2018

www.vompti.com

# Lower Extremity Injuries: Is It Just About Hip Strength?

BRYAN C. HEIDERSCHEIT, *PT, PhD*

*J Orthop Sports Phys Ther* 2010;40(2):39-41. doi:10.2519/jospt.2010.0102



Orthopaedic Manual Physical Therapy Series 2017-2018

www.vompti.com