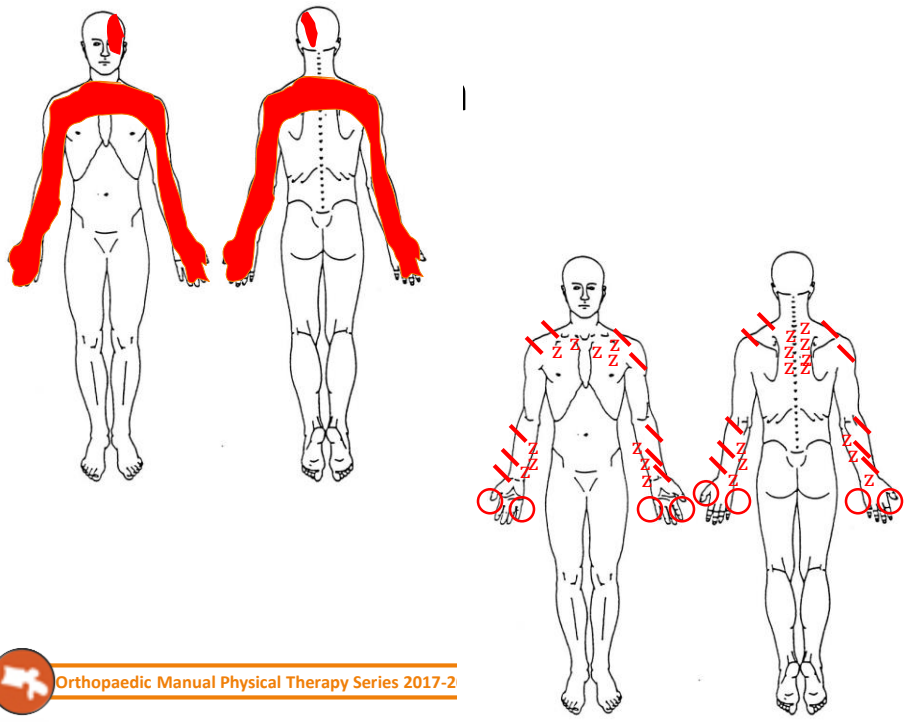
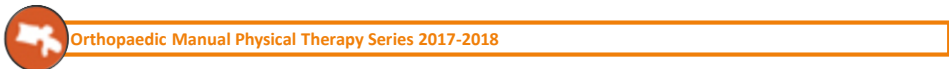



THORACIC OUTLET SYNDROME

Michael McMurray PT, DPT, OCS, FAAOMPT

Orthopaedic Manual Physical Therapy Series
Charlottesville 2017-2018



- ⊙ Shoulder-hand syndrome
- ⊙ Cervical rib syndrome
- ⊙ Scalenus anticus syndrome
- ⊙ Costoclavicular syndrome
- ⊙ Hyperabduction syndrome
- ⊙ Pneumatic hammer syndrome
- ⊙ Fractured clavicle syndrome
- ⊙ Effort vein thrombosis
- ⊙ Pectoralis minor syndrome
- ⊙ Subcoracoid syndrome
- ⊙ First thoracic rib syndrome
- ⊙ Brachiocephalic syndrome
- ⊙ Humeral head syndrome
- ⊙ Nocturnal paresthesia brachialgia
- ⊙ Cervicobrachial neurovascular compression syndrome
- ⊙ Rucksack paralysis
- ⊙ Cervicothoracic outlet syndrome
- ⊙ Syndrome of the scalenus medius band

TOS ?



Thoracic Outlet Syndrome

- Syndrome
 - a group of symptoms that consistently occur together or a condition characterized by a set of associated symptoms.

- WHERE and not WHAT the problem is
 - Compression of brachial plexus or subclavian artery and/or vein at the upper thoracic region



“...the most underrated, overlooked and misdiagnosed peripheral nerve compression in the upper extremity...”

- Roos BD. The Thoracic Outlet is **underrated**. Arch Neuro. 1990; 47: 327-328
- Wilbourn AJ. The thoracic syndrome is **overdiagnosed**. Arch Neuro. 1990; 47: 328-330.



Thoracic Outlet Syndrome

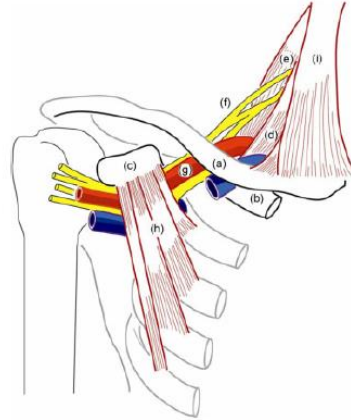
- Lesson in Clinical Reasoning
 - ‘Comprehensive examination of every structure from which symptoms could be arising’
 - Phillips and Grieve(1986)
 - ‘...*foggy* concept makes difficulties, by initiating a *wild goose chase* for the single site of impingement when none may exist.’
 - Grieve (1994)



Diagnosis of Exclusion

Differential Diagnosis

- CTS
- De Quervain's
- Lateral Epicondylalgia
- Medial Epicondylalgia
- CRPS
- Horner's Syndrome
- Raynaud's
- Cervical DDD/DJD
- UE – DVT
- RTC pathology
- GH instability



Thoracic outlet syndrome: a controversial clinical condition. Part 1: anatomy, and clinical examination/diagnosis

Troy L. Hooper¹, Jeff Denton², Michael K. McGilliard^{1,3}, Jean-Michel Brismée^{1,3}, Phillip S. Sizer Jr^{1,3}

Journal of Manual and Manipulative Therapy 2010 VOL. 18 NO. 2

Thoracic outlet syndrome: a controversial clinical condition. Part 2: non-surgical and surgical management

Troy L. Hooper¹, Jeff Denton², Michael K. McGilliard^{1,3}, Jean-Michel Brismée^{1,3}, Phillip S. Sizer Jr^{1,3}

Journal of Manual and Manipulative Therapy 2010 VOL. 18 NO. 3



Incidence

- Vascular
 - <5% of TOS
 - 1% Arterial
 - 3-5% Venous
 - Majority 20-50 yo
 - Equal b/n men and women
 - Athletic men > women
 - Ischemic
 - (+) Diagnostic Testing
 - Never disputed
- Neurogenic
 - 90-97% of TOS
 - Women 3-4x more likely
 - (-) Diagnostic Testing
 - True or Disputed Neurogenic



Arterial TOS (1%)

- Upper limb ischemia
- Multiple upper limb arterial embolization
- Acute hand ischemia
- Claudication
- Vasomotor phenomena
- Digital gangrene
- Absent or decreased arterial pulse
- Swelling, feeling of stiffness/heaviness, fatigability, coldness, pain of muscle cramp in the upper limb or hand
- Paresthesia (due to ischemia)
- (+) Arteriogram

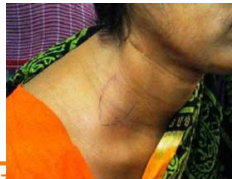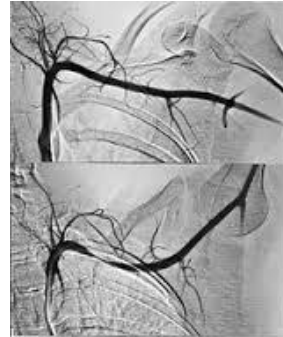


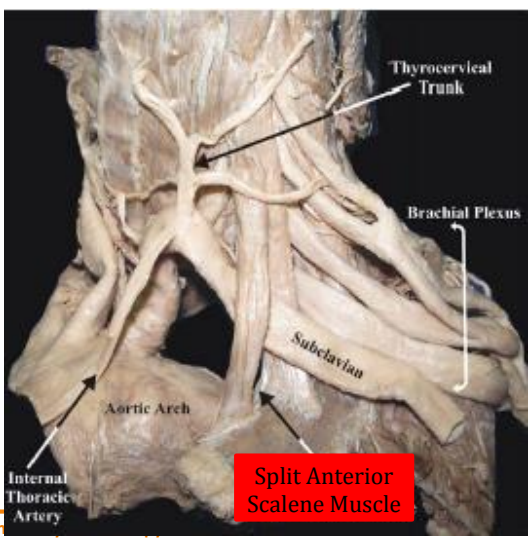
Fig. 1: Swelling in neck

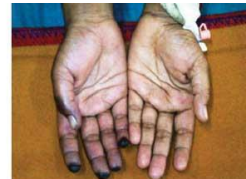

Fig. 2: Blackish discoloration of fingertips of right hand



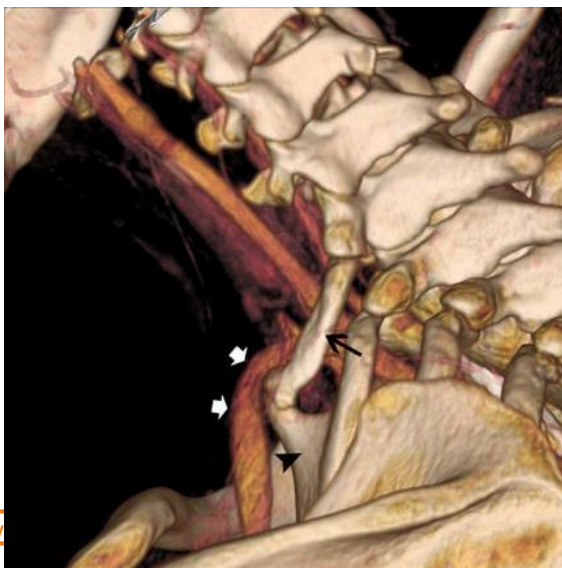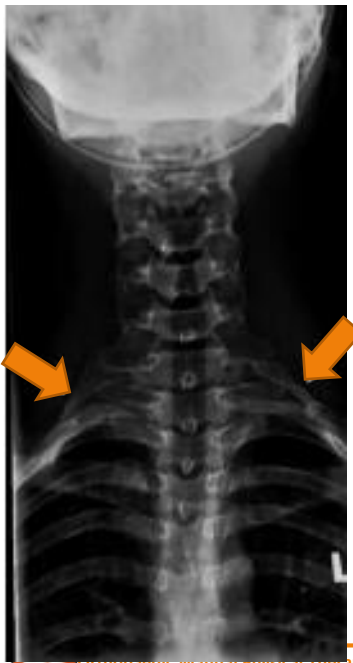
Anomalies: Split Scalene



Orthopaedic Manual Physical Therapy

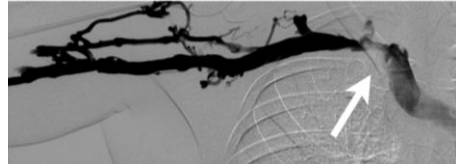
www.vompti.com

Anomalies: Cervical Rib



Orthopaedic Manual Physical Therapy

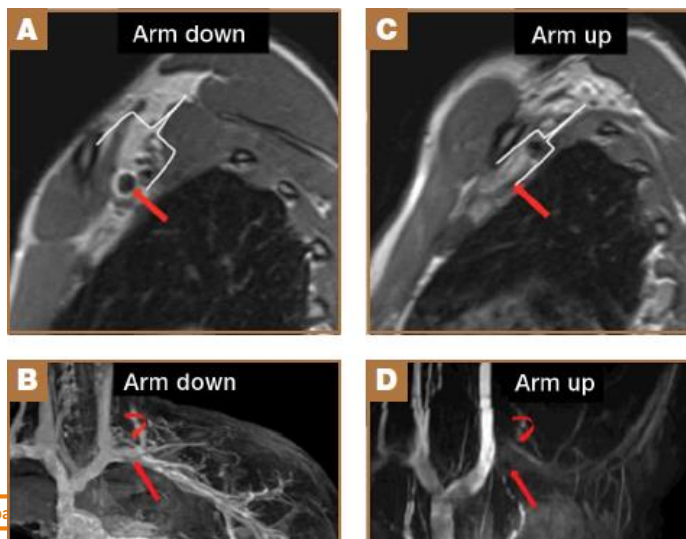
Venous TOS (3-5%)



- Asymmetrical upper extremity edema
- Pain, cyanosis, fatigability & a feeling of stiffness or heaviness of the upper extremity
- Venous engorgement w/ collateralization of peripheral vessels
- Axillary or subclavian vein thrombosis
- Pulmonary embolism
- Paresthesia
- (+) Venogram

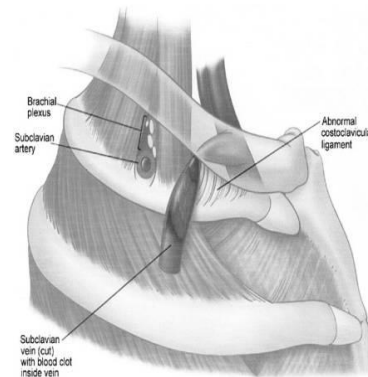


Subclavian Vein Compression in Costoclavicular Space



Paget-Schroetter Syndrome

- Effort thrombosis
- Axillary-subclavian vein thrombosis
- 10-20% of UE DVT
- Repetitive overhead UE use
- Symptoms
 - Swelling and arm discomfort
 - Heaviness, redness of arm, cyanosis and dilated, visible veins across the shoulder and upper arm (Urschel's sign)



True Neurogenic TOS

- True Neurogenic (< 1%) → Identifiable cause (anomaly)
- (+) Diagnostic Testing
- (+) Objective Neuro Testing
- Pain worse during the day: “compressors”
- Cervical Pain, sometimes facial
- Paresthesia – Typically lower truck – Ulnar distribution
- Tenderness Scaleni, Trapezius, Pecs
- Hypertrophy/Fibrosis Scaleni
- Decreased sensation fingers
- (+) Provocation tests
- Atrophy Thenar/Hypothenar
- **(+) EMG, Imaging Findings**

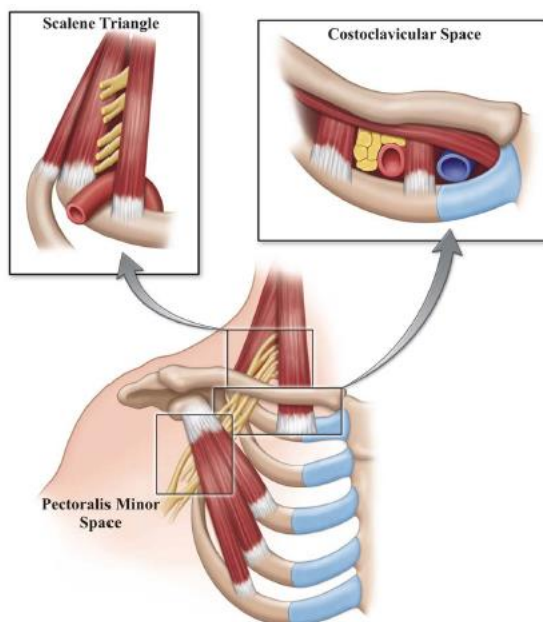


Disputed Neurogenic TOS

- Most > 99% Mixed, Symptomatic, Non specific
- (-) Objective Neuro Testing
- Pain worse at night: “Releasers”
- Cervical Pain, sometimes facial
- Paresthesia – Typically lower truck – Ulnar distribution
- Tenderness Scaleni, Trapezius, Pecs
- Hypertrophy/Fibrosis Scaleni
- Decreased sensation fingers
- (+) Provocation tests
- Atrophy Thenar/Hypothenar
- **(-) EMG, Imaging Findings**

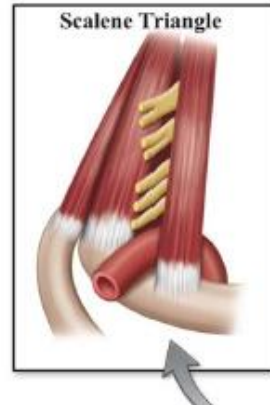


Potential Areas for Compression



Compression Sites

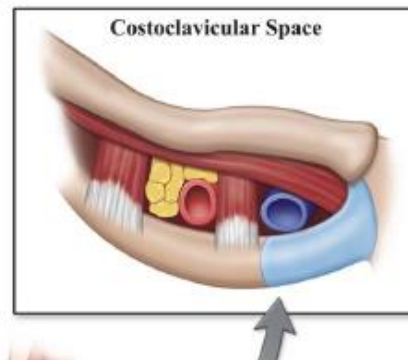
- Interscalene Triangle
 - Lower trunk and Subclavian artery pass between Ant/Middle Scalene
 - Anomalies
 - Cervical rib
 - 1st rib angulation
 - Large C7 TP



Orthopaedic Manual Physical Therapy Series 2017-2018

Compression Sites

- Costoclavicular Space
 - Lower trunk crosses over 1st rib and under clavicle to enter Subclavicular fossa with Subclavian artery and vein passing under Subclavius
- Sensitive to Shoulder Abduction as clavicle moves posterior

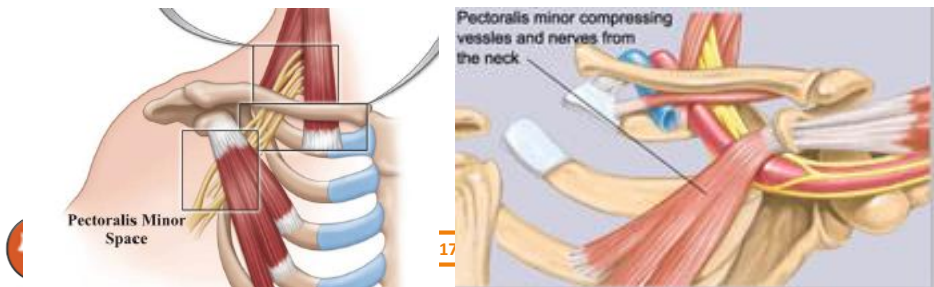


Orthopaedic Manual Physical Therapy Series 2017-2018

www.vompti.com

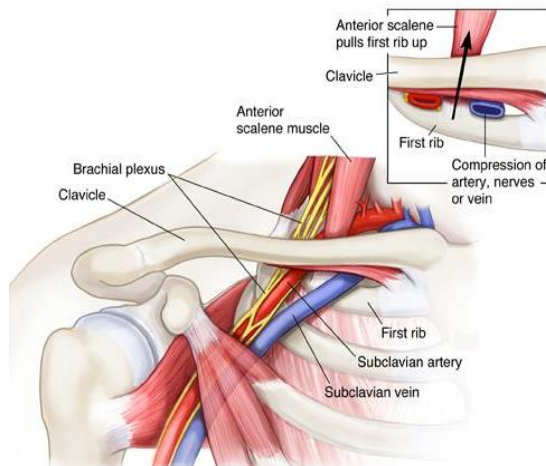
Compression Sites

- Retro Pectoralis Minor Space
 - Lower trunk passes under Pec Minor near coracoid process
- Sensitive to Shoulder Hyperabduction
 - pec minor tendon & coracoid become a fulcrum that the neurovascular structures are forced to change directions



Possible Structures at Fault

- Cervical Rib (anomalies)
- First Rib (elevated)
- Pec Minor (tight/spasm)
- Scalene anterior/middle (hypertrophic/fibrotic)
- Anterior Capsule of GH Jt (unstable/lax)
- Clavicle (fracture callous)



Test Interpretation and Treatment Planning

TOS provocation tests*	Thoracic outlet container testing†	Peripheral nerve provocation tests‡	Interpretation	Management decisions
(-)	(-)	(-)	Low suspicion for TOS and or peripheral nerve irritation/entrapment condition. Symptoms are likely due to other condition, such as cervical spine or central nervous system.	Further testing merited before management is initiated
(+)	(-)	(-)	High suspicion for TOS without associated thoracic outlet container dysfunction; low suspicion for peripheral nerve irritation/entrapment	Treat TOS for symptom management
(+)	(+)	(-)	High suspicion for TOS with associated thoracic outlet container dysfunction; low suspicion for peripheral nerve irritation/entrapment	Treat TOS for symptom management and improvement of thoracic outlet container mobility
(+)	(-)	(+)	High suspicion for TOS without associated thoracic outlet container dysfunction; high suspicion for peripheral nerve irritation/entrapment	Treat TOS for symptom management; treat peripheral nerve irritation/entrapment
(+)	(+)	(+)	High suspicion for TOS with associated thoracic outlet container dysfunction; high suspicion for peripheral nerve irritation/entrapment; high suspicion for double crush	Treat TOS for symptom management and improvement of thoracic outlet container mobility; treat peripheral nerve irritation/entrapment
(-)	(+)	(+)	Low suspicion for TOS; high suspicion for thoracic outlet container dysfunction; high suspicion for peripheral nerve irritation/entrapment; high suspicion for double crush.	Treat for improvement of thoracic outlet container mobility; Treat peripheral nerve irritation/entrapment
(-)	(-)	(+)	Low suspicion for TOS; low suspicion for thoracic outlet container dysfunction; high suspicion for isolated peripheral nerve irritation/entrapment; low suspicion of double crush.	Treat peripheral nerve irritation/entrapment

*For any UE symptoms; A (+) cluster of tests increases the suspicion.

†For mobility loss/dysfunction in any joint system in the container, such as first rib, ACJ, or SCJ.

‡For specific peripheral nerve symptoms provoked through peripheral nerve clinical provocation testing.

Assessment

- Subjective Special Questions
- Postural Assessment
- Cervical Screen
- Shoulder/Scapular Screen
- Neurologic Assessment
- First Rib Assessment
- Provocative Testing



Subjective Exam

- Special Questions
 - Vascular Symptoms
 - Coldness, swelling, discoloration, heavy, “dead arms”
 - Symptoms increase with overhead work
 - Symptoms increase with exertion
 - Symptoms worse at night or during the day
 - Symptoms increase with carrying backpack or carrying items by your side
 - History of clavicle fracture, shoulder pathology/dislocations

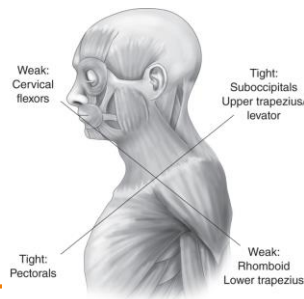
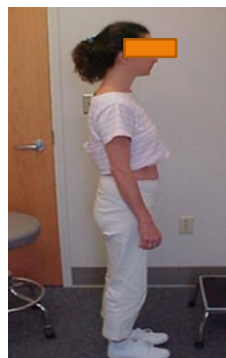


Orthopaedic Manual Physical Therapy Series 2017-2018

www.vompti.com

Postural Faults

- Upper Quarter Crossed Syndrome
- ↑ tone - Scalenes, Upper Trap, Levator Scapulae
- CT Dowagers
- High Thoracic Spine Lordosis (elevated upper ribs)
- Forward Head; ‘Drooping Shoulders’- Chronically contracted pec minor

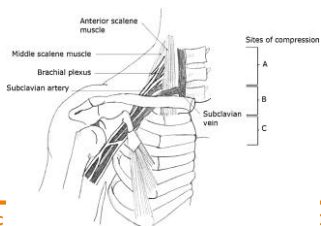


Orthopaedic Manual Physical Therapy Series 2017-2018

©Human Kinetics 2010

“Double Crush”

- Proximal dysfunction -> impaired neural function -> altered axoplasmic flow -> intraneural fibrosis -> ischemia and/or mechanical deformation -> extraneural irritation = Distal symptoms
 - C7 and Carpal Tunnel Syndrome
 - L5 and Lateral Ankle Sprain

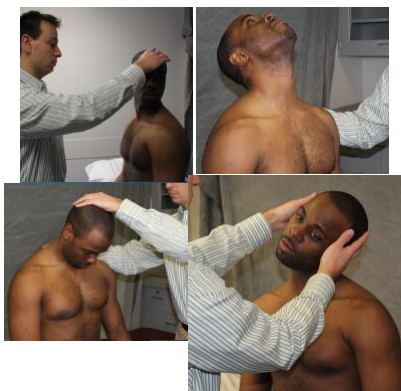

Orthopaedic

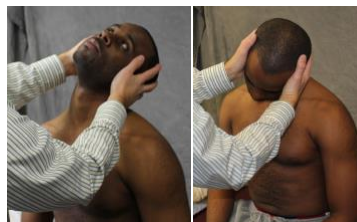18

Cervical Screen

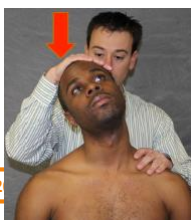AROM with OP



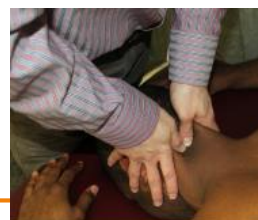Quadrants



Spurlings

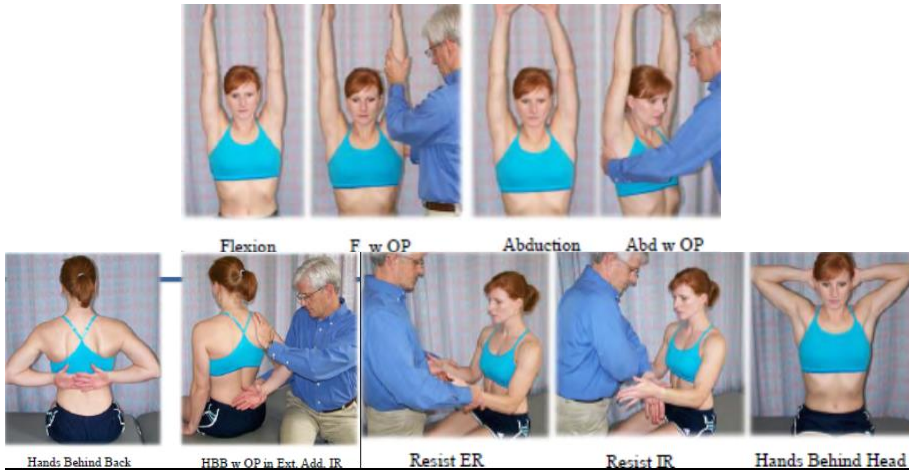


PAIVM/PA's



Orthopaedic Manual Physical Therapy Series 2

Shoulder Screen

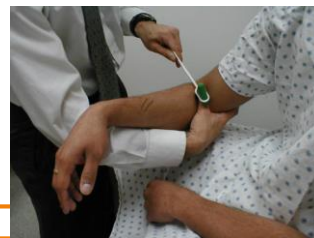
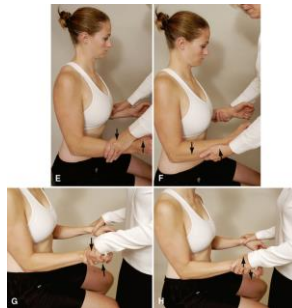
Orthopaedic Manual Physical Therapy Series 2017-2018

www.vompti.com

Neurologic Exam

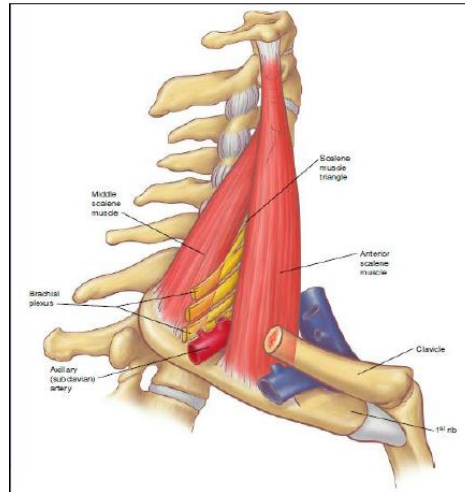
- DTR
- Myotome
- Sensation
 - Sharp/Dull
- UMN
 - Hoffman/Clonus



Orthopaedic Manual Physical Therapy Series 2017-2018

Rib Joint Pathomechanics – 1st Rib

- Ant/Middle Scalene insertion
- Lower plexus trunk
- Elevation > Depression
 - Scalene hypertrophy
 - Upper chest breather
 - Prone rotation sleeper
 - Computer/ergonomics

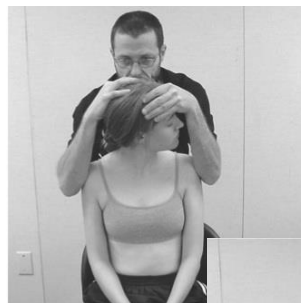


Orthopaedic Manual Physical Therapy Series 2017-2018

www.vompti.com

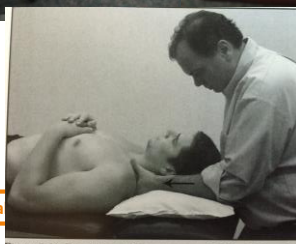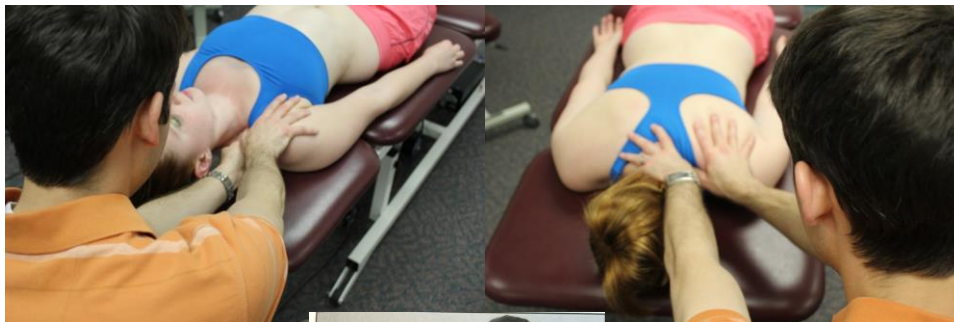
Cervical Rotation-Lateral Flexion Test

- Examine mobility of 1st rib
- Pt sitting
- C/S passively and maximally rotated **AWAY** from side being tested
- Gently flex as far as possible, moving ear toward the chest
- (+) if lateral flexion is limited or blocked (+ R and - L)
- Excellent interrater reliability $K = 1.0$ and good agreement with cineradiographic findings $K = .84$



Orthopaedic Manual Physical Therapy Series 2017-2018

1st Rib PAIVM Assessment



Orthopaedic Manual Physical

www.vompti.com

Roos Stress Test

Elevated Arm Stress Test (EAST)

- Patient seated with arms >90 deg abduction and full ER
- Patient open and closes hands into fists for 3 minutes
- (+): pain and/or parasthesia and dropping arms for relief
- High amount of false positives
- Tests scalene, costoclavicular and axillary intervals



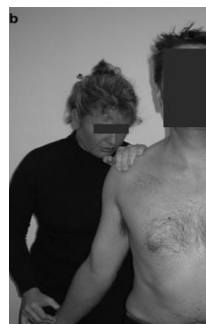Orthopaedic Manual Physical

www.vompti.com

Wrights Test

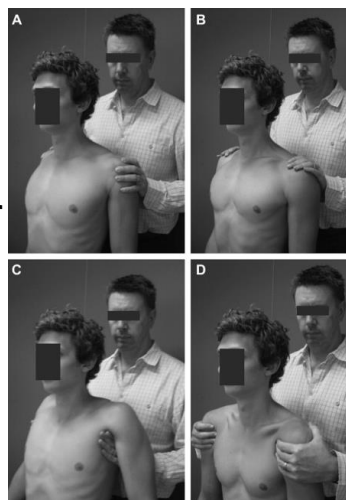
Hyperabduction Maneuver

- Patient seated arms at side
- Assess radial pulse
- Examiner places pt shoulder into 90 abduction and then repeated in hyperabduction (end range abduction)
- (+): Pulse change and/or symptom reproduction
- Tests :
 - Axillary Interval (post to pec minor) (Part 1)
 - Costoclavicular Interval (Part 2)



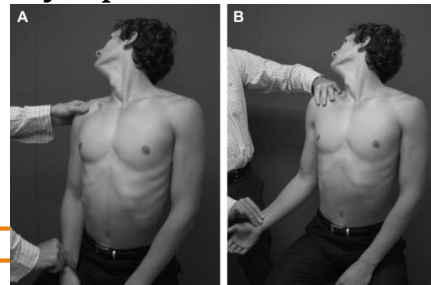
Costoclavicular Maneuver

- Patient seated with arms at side.
- Examiner assists patient in retraction, depression, elevation and protraction of scapula.
- Each position is held for 30 sec
- (+): Symptom reproduction
- Tests Costoclavicular Interval



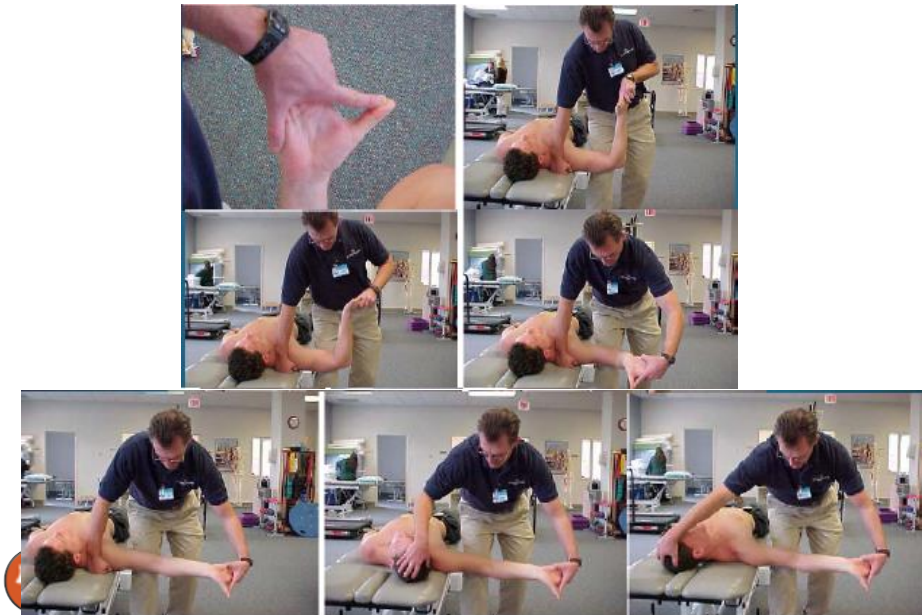Adson's Maneuver

- Patient seated, arms at side
- Patient performs cervical rotation and extension toward test side
- Patient takes a deep breath and holds for 30 sec as pulse is assessed
- (+): Pulse change and/or symptoms reproduction
- Tests Scalene Triangle



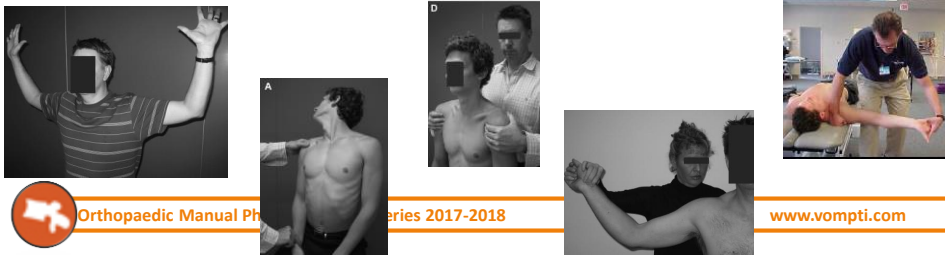Orthopaedic Manual Physical Therapy Series 2017-2018

ULPT 1: Median Nerve Bias



TOS Clinical Test Psychometrics

	Sensitivity	Specificity	+ LR	- LR
EAST	52-84	30-100	1.2-5.2	0.4-0.53
Adson's	79	74-100	3.29	0.28
Costoclavicular Maneuver	N/T	53-100	N/A	N/A
Wright's	70-90	29-53	1.27-1.49	0.34-0.57
ULPT 1	90	38	1.5	0.3



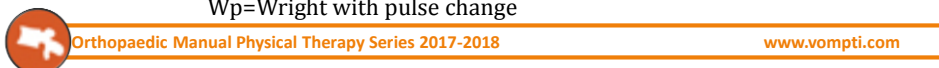Diagnosing thoracic outlet syndrome: contribution of provocative tests, ultrasonography, electrophysiology, and helical computed tomography in 48 patients

Joint Bone Spine 2001 ; 68 : 416-24

Table IV. Correlation between pairs of provocative tests and the final diagnosis.

<i>Provocative tests</i>	<i>SE</i>	<i>SP</i>
Adson + Ws	79	76
Adson + Roos	72	82
Adson + HAs	72	88
Adson+Wp	54	94
Ws + Roos	83	47
Ws + HAs	83	50
Wp + HAs	63	69

Ws= Wright with symptom provocation
 HAs=Hyperabduction with symptom provocation
 Wp=Wright with pulse change



TOS - Treatment

- Postural Education
- Ergonomics
- Scalene/Pectoralis minor
 - STM
 - Flexibility
- First rib mobilization – Inferior/Medial glide
- Diaphragmatic breathing
- Activate/Strengthen anterior cervical flexors
- Scapular Positioning/control
- CT mobilization
- GH posterior capsule stretch
- Neural mobilization
- ? Other



Orthopaedic Manual Physical Therapy Series 2017-2018

www.vompti.com

Treatment for thoracic outlet syndrome (Review)

Povlsen B, Belzberg A, Hansson T, Dorsi M

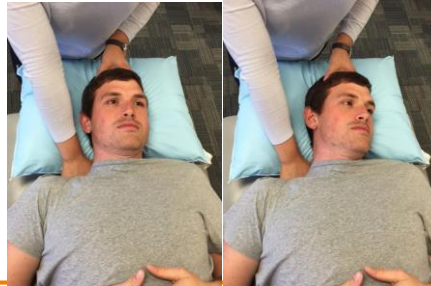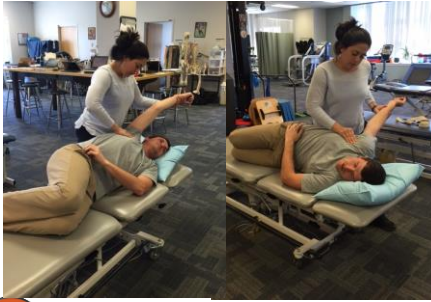
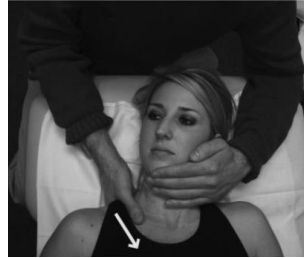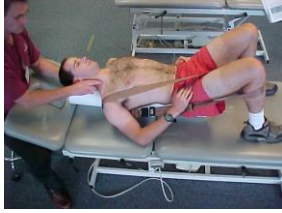Cochrane Database of Systematic Reviews

Authors' conclusions

This review was complicated by a lack of generally accepted diagnostic criteria for the diagnosis of TOS. There was very low quality evidence that transaxillary first rib resection decreased pain more than supraclavicular neuroplasty, but no randomized evidence that either is better than no treatment. There is moderate evidence to suggest that treatment with BTX injections yielded no great improvements over placebo injections of saline. There is no evidence from RCTs for the use of other currently used treatments. There is a need for an agreed definition for the diagnosis of TOS, especially the disputed form, agreed outcome measures, and high quality randomized trials that compare the outcome of interventions with no treatment and with each other.

Cochrane Database of Systematic Reviews 2014, Issue 11.

Manual Therapy Techniques: Soft Tissue




Orthopaedic Manual Physical Therapy Series 2017-2018

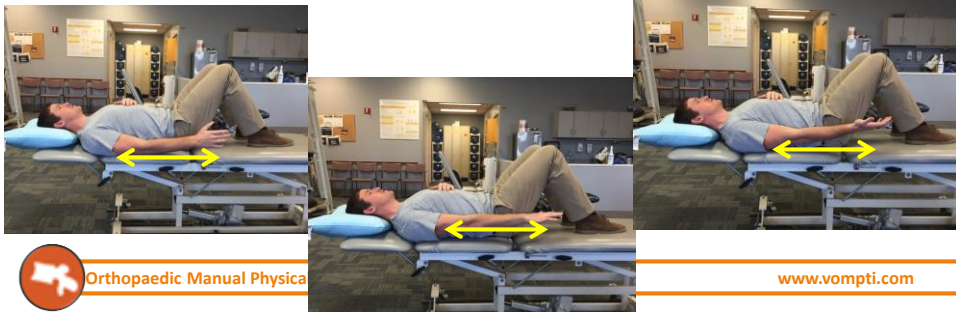
www.vompti.com

Manual Therapy Techniques: Neural Glides

- Proximal Nerve Glides



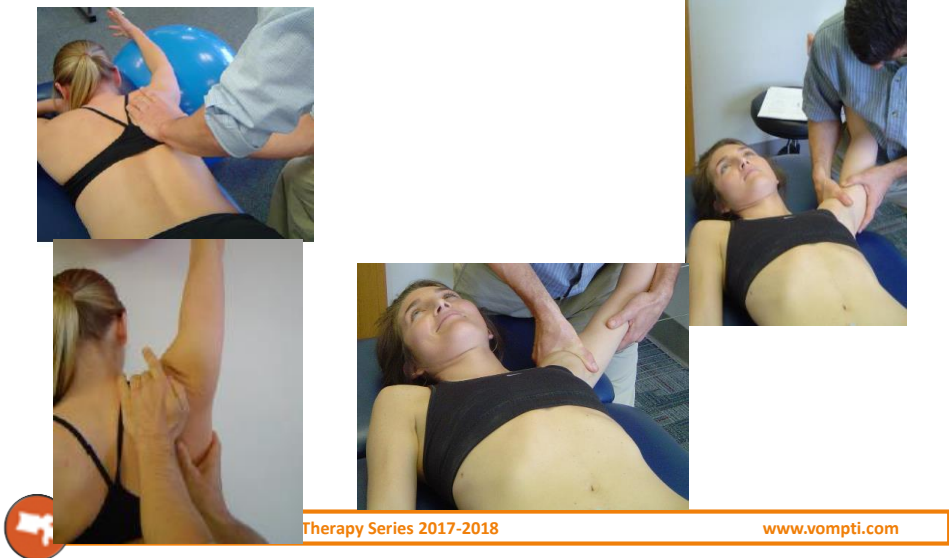- Self Nerve Glides



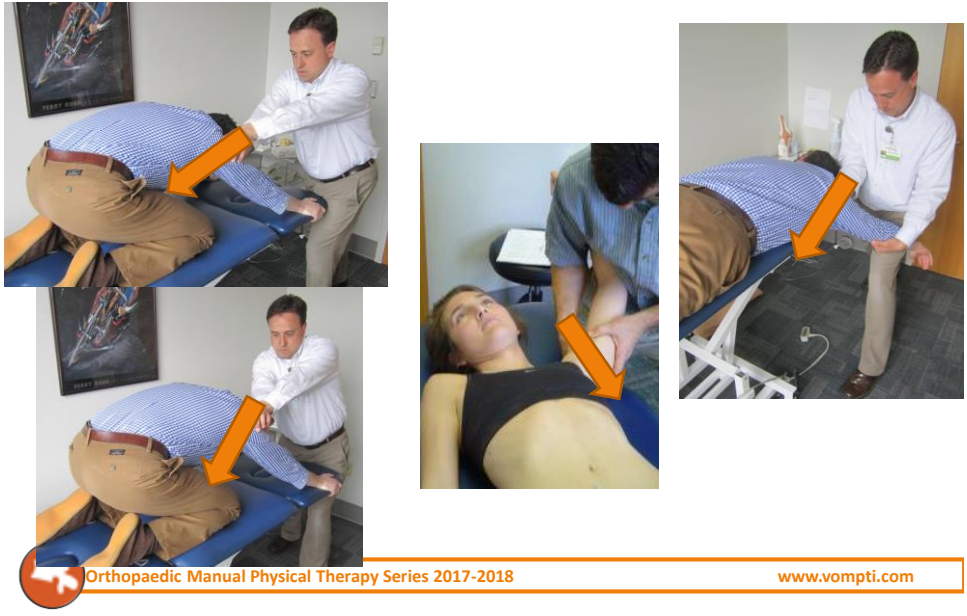Orthopaedic Manual Physical Therapy Series 2017-2018

www.vompti.com

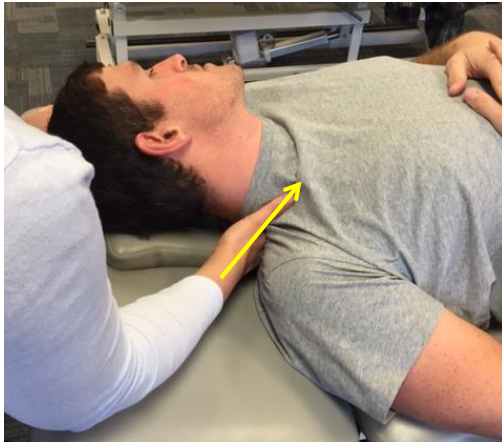Manual Therapy Techniques: Shoulder/Scapular Techniques



End Range GH Glide



1st Rib Treatment: Mobilization



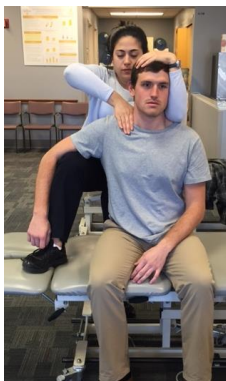Costovertebral Mobilization
Caudal/Contralateral Force



Orthopaedic Manual Physical Therapy Series 2017-2018

www.vompti.com

1st Rib Treatment: MET



Treating Right 1st Rib



- Stand behind patient with involved arm resting on your thigh
- With ipsilateral 2nd MCP locate shaft of 1st rib
- Slightly SB patient's head toward and sidebend away
- Hold position and have patient gently push into contralateral sidebend
- Hold x 6 sec and on relaxation take up slack

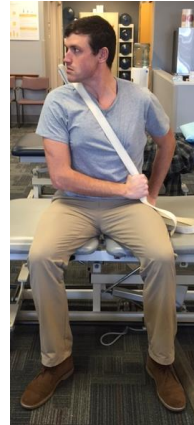
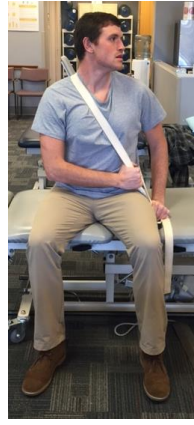
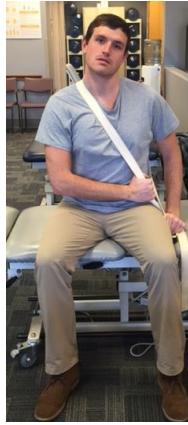
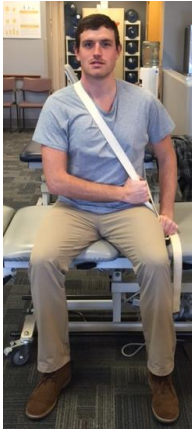
Orthopaedic Manual

2018

www.vompti.com

1st Rib Treatment: Self Mobilization



1st Rib Emphasis

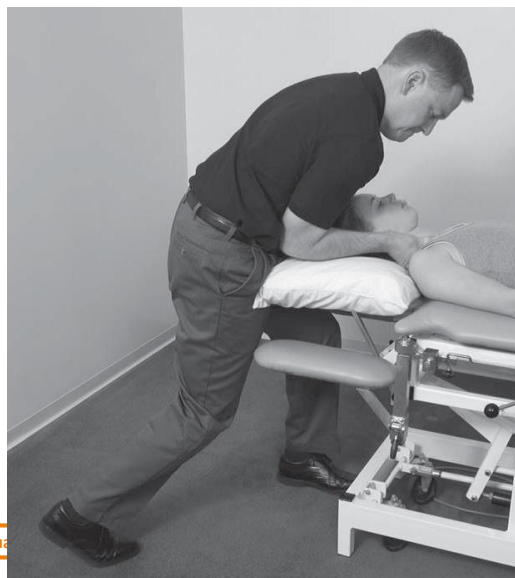Scalene Stretch Emphasis



Orthopaedic Manual Physical Therapy Series 2017-2018

www.vompti.com

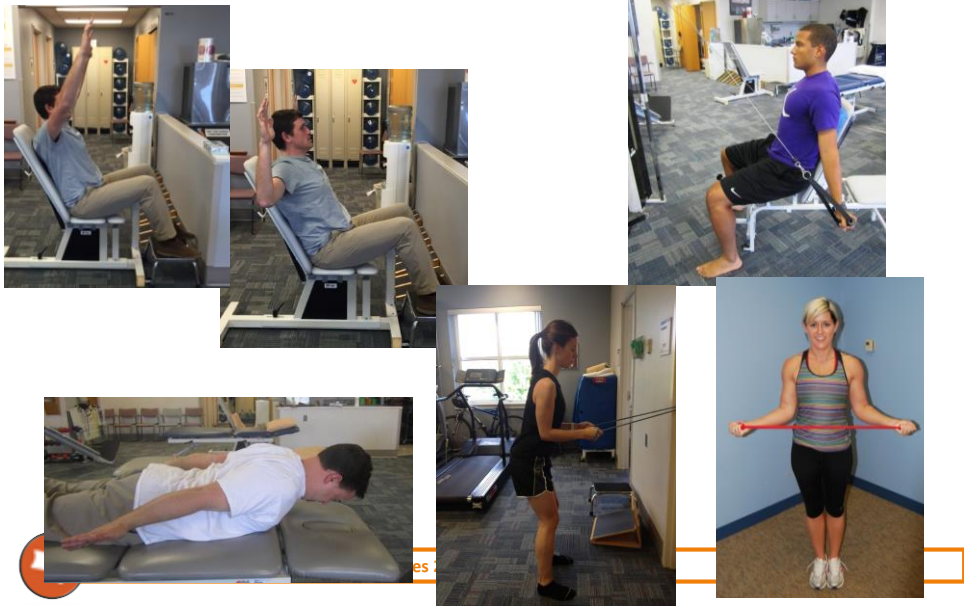
1st Rib Treatment: Manipulation ("Snooker" Technique)



Orthopaedic Manual

www.vompti.com

Therapeutic Exercise



Therapeutic Exercise

